

Treatment of rhinoceros which have been poached using opioids and are found recumbent

Leith Meyer¹, Roy Bengis², William Fowlds³, Amelia Goddard⁴, Markus Hofmeyr^{1,5}, Johan Marais⁴, Jacques O'Dell⁶, Gerhard Steenkamp⁴, Adrian Tordiffe^{4, 7}, Mike Kock⁶

¹Dept of Paraclinical Science, Faculty of Veterinary Science, University of Pretoria, Leith.meyer@up.ac.za

²Retired State Veterinarian, Kruger National Park

³Private Practitioner, Wildlife Vet, Investec Rhino Lifeline

⁴Dept of Companion Animal Clinical Studies, Faculty of Veterinary Science, University of Pretoria,

⁵Veterinary Wildlife Services, SANParks

⁶Dept of Production Animal Studies, Faculty of Veterinary Science, University of Pretoria,

⁷Dept of Research & Scientific Services, National Zoological Gardens,



1. Introduction

The trauma and emotion of confronting a scene where a rhino is still alive and immobilized with its horn “hacked off” or wounded does not bode well for making rational and good decisions about treatment. In addition, unlike our domesticated species, we know very little about optimal treatment in rhino and because of the sheer size and complexity of their physiology and how they respond to drugs, our job of treating these animals often leads to a great deal of uncertainty and distress. Therefore, after lengthy consultation and discussion with field practitioners and academics, we have formulated this document so that you are able to give, what we believe is, optimal field treatment so that these animals have the greatest chance of recovery and survival. We have also included some details on samples needed for research on prognostic indicators in these patients, and summary sheets which may help with potential planning and information you may need in the field.



2. Understanding what is happening in these animals

Understanding the physiological changes that are taking place in these poached recumbent animals is essential in order for you to treat them appropriately. Because of the ruthless way in which their horns are removed, they may have bled profusely before you arrive at the scene, and are therefore most likely to be hypovolaemic, hypotensive and dehydrated.

These rhinos would have been immobilized with etorphine or thiafentanil¹ and therefore will have chronic opioid-induced respiratory depression; in white rhino this depression is far worse than in black rhino. The depression results in severe hypoxia, hypercapnoea and respiratory acidosis, and because

¹To our knowledge the drugs used by poachers are currently opioids but we suspect these agents may diversify to anything possible (e.g. neuromuscular blocking agents) in the future so it is worth keeping our minds open to this.

these animals are usually only found a number of hours after the poaching incident they may be severely compromised by these effects. Hypoxia will result in anaerobic metabolism leading to a metabolic lactic acidosis, compounding the respiratory acidosis. It will also result in global cellular dysfunction, cell damage or necrosis and in combination with the acidaemia there will be electrolyte shifting and most likely a hyperkalaemia and other electrolyte-induced cellular disruptions.

If an animal is in lateral recumbency for a prolonged period of time there will be cardiorespiratory abnormalities that will further compound the opioid-induced respiratory depression. The lung lobes closest to the ground will be congested from blood stasis and there may be profound atelectasis resulting in a severe ventilation-perfusion mismatching and blood shunting which will hinder the diffusion of oxygen into the blood, further exacerbating hypoxia. Even if the animals are in sternal recumbency some of these effects may even occur in ventral and peripheral lung regions because of prolonged hypoventilation and poor perfusion.

Prolonged recumbency causes severe compression of muscles and nerves that are pressed against the ground, resulting in "crush injury". Compression results in blockage or decreases blood flow causing pooling of blood in tissues. The compressed tissue will become hypoxic and there will be cellular dysfunction and necrosis which will result in an accumulation of metabolic by-products, myoglobin, electrolytes and inflammatory mediators in the pooled blood. If the compression is relieved suddenly it may result in reperfusion injury where these substances, many of which are potent vasodilators, will flood the systemic circulation and may result in a drop in blood pressure, which in already hypovolaemic patients may result in circulatory shock. Furthermore, the existing hyperkalaemia will be exacerbated when this pool of blood is released, and if severe enough the animals may suffer cardiac arrhythmias and arrest. Once an ischaemic area receives fresh oxygenated blood the formation of toxic hydroxyl free-radicals may occur and these may further damage tissues. If an animal survives these acute effects there is a chance that they may suffer from the chronic consequences of this compression. These consequences include severe neuropathies and extensive myopathy causing immediate lameness or delayed effects which could include severe myoglobin-induced renal failure and muscle necrosis resulting in compartment syndrome and even muscle belly rupture. In addition, some of these rhinos may have been shot and while they may have sustained relatively "minor" injuries from the gunshot, there may be deeper musculoskeletal injuries that need to be addressed.

In summary these animals generally have a severely compromised physiology that needs to be carefully managed in order for these animals to survive the acute and chronic consequences of a prolonged immobilization with severe haemorrhage and trauma.



Goals of Treatment

The primary goal is to stabilize the patient so that when the reversal of the immobilizing drugs is given the animal is able to stand, fend for itself with a reduced risk of developing life threatening post-immobilization and wound complications. Should these measures delay the administering of the pure antagonist by more than an hour, they should be carefully reconsidered. Further wound treatment can be done in a less compromised patient 48 hours later. The treatment is also aimed at reducing the severe consequences of crush injury like myoglobin-induced renal failure, and to reduce wound contamination, help with initial healing and prepare the wound for future treatment.



The benefits of these treatments must be weighed up against the time delays likely in administering these measures, operate adaptively.



What to do?

If confronted with one of these poaching incidences get the rhino owner/client to contact the relevant authorities while you are rushing to their property. If you are unsure of the legal procedures contact the local state prosecutor or Environmental Management Inspectors (see the list of contact details below). If the animal is found alive, as we are discussing here, the veterinarian needs to attend to the animal first. Only then can the authorities investigate the scene. However, while doing your job it is important to be aware of and preserve evidence (foot prints around the carcass, fingerprints on darts etc.) before starting with your life saving procedures (see the section on dead animals and forensics below). Before arrival try and ensure that a good resolution camera and or video camera is available. Detailed photography by an observer or better continuous video will be helpful retrospectively.

When you arrive on the scene the degree of consciousness of the animal, and hence risk to personal, must be assessed. Before treatment, it is essential to do a quick clinical exam which should include TPR (see some normal variables in Table 1 below), auscultation of the heart and lungs, assessment of oxygenation and hydration status through the examination of mucous membranes and blood, assessment of the severity of the wound and estimation of blood volume lost. If the animal is still bleeding severely, haemostatic measures should be instituted while you stabilize the animal. Placement of a blind fold and earplugs should be done to limit external stimulus - minimising stress in these animals is essential. If an animal is partly “awake” one could consider administering 500mg of ketamine to temporarily deepen the immobilization so that it is easier to work with the animal and to reduce its exposure to pain and stressful stimuli.

Before administering treatment it is essential to stabilize the cardiorespiratory system. Partial reversal with butorphanol (15-30mg IV – more can be given by titration if needed but beware that black rhino are more sensitive to partial antagonists than white rhino) is important to improve breathing but its effects are only moderate at the best of times and because of the severe ventilation-perfusion mismatching these animals will remain severely hypoxic. It is therefore advisable to insufflate these animals with oxygen; this can be done by inserting a tube deep into the nasal passages. Oxygen

should be administered at greater than 10 - 15 L.min⁻¹ and should only be given after butorphanol has been administered². The next step is to catheterize a vein and collect blood samples in serum, EDTA, heparin, fluoride and citrate tubes (in this order; refer to sample management below). Although blood collection will not save the animals life initially, these samples will be essential to help you motivate and justify your future treatments and actions and therefore will not be time wasted³ (blood should also be collected at subsequent immobilizations and treatments).

To correct hypovolaemia, reduce reperfusion injury and minimise the nephrotoxic effects of myoglobin we recommend crystalloid (0.9% Saline, avoid potassium containing fluids like Ringers Lactate if you can)⁴ should be given at shock doses; get as much fluids as you can into the animal within an hour - this may mean that 20 - 40L of fluids should be infused. Large bore catheters (14-16G) should be placed in as many veins as possible (try the auricular, medial saphenous and cephalic veins) and run the fluids through all of these catheters as fast as possible. Fluids (water) can also potentially be administered per rectum. Vitamin E (Kyron Laboratories) can also be given for its antioxidant effects at a dose of 10 IU/kg IM⁵.

Appoint a responsible person (preferably owner) to get a ground crew assembled to assist with fetching equipment and repositioning the animal. After 15 min of fluid infusion, slowly move the animal so that the compressed limbs are freed. If an animal has been lying in sternal recumbency it can be placed laterally, but should be moved regularly so that the limbs don't get compressed for too long in one position. If it has been lying in lateral recumbency, it can be moved sternal, so that it lies partially to one side to relieve the pressure off the limbs that were compressed (be careful that you don't compress the healthy legs for too long). **DO NOT** move these laterally lying animals **to the opposite lateral position** as this may kill the animals from the sudden shift and change in vascular fluid dynamics, or it may severely compromise their normally functioning lung regions and cause respiratory failure. Another option for animals that have been found in lateral or even sternal recumbency is to partly roll them onto their backs enough to relieve the compressed areas of the body, especially the limbs. This position has the advantage that it does not cause compression of any of the limbs, and as far as we are aware, at this stage, it does not severely compromise the animal. Proper strapping placed around the feet and a vehicle can be used to move and keep the animal in this position; foam padding or a mattress may also help.

While the fluids are running in, and the animal is lying so that the compressed limbs are re-perfused with blood, monitor the animals closely for a few minutes to ensure that they are stable and there are

² If your oxygen supplies are limited, oxygen can be given to effect but oxygenation should be monitored closely. To achieve this pulse oximetry can be used but it is often inaccurate and unreliable in pachyderms so it should be used with caution. In our opinion assessing the colour of arterial blood is best. To get arterial blood a 22G catheter can be placed in the median artery in the inner ear after the vessels is stimulated to dilate by vigorous rubbing (arterial catheterization may be difficult in severely hypovolaemic animals). Mucous membrane colour may also be useful but may also be difficult to accurately assess in these animals.

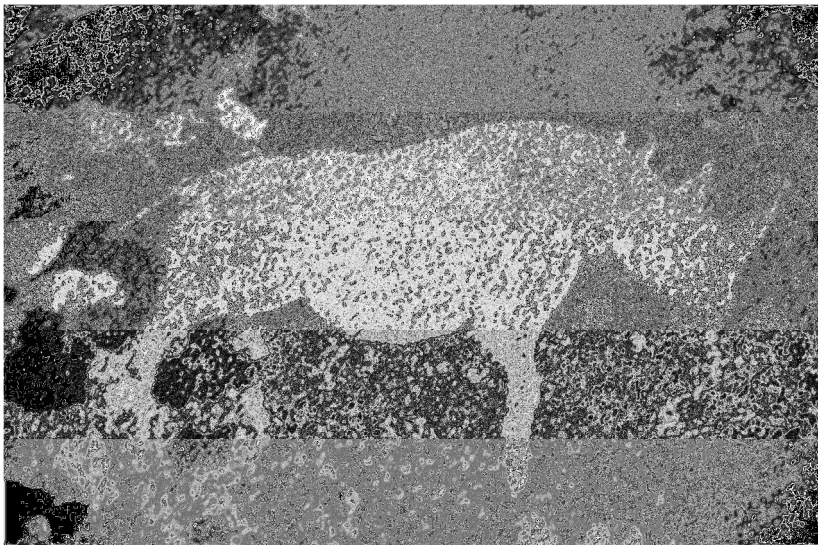
³ If you have the equipment to determine arterial blood gases, blood lactate and electrolyte levels in the field, this data may prove invaluable to help you evaluate the immediate effectiveness of your treatment and prognosis.

⁴ Colloid fluids (e.g. Voluven, Gelofusine) at 5-10ml/kg will also be of great benefit when added to the crystalloids.

⁵ Prednisolone sodium succinate (Solu-Delta-Cortef, 0.25-0.1 mg/kg IV) or dexamethasone (0.2 mg/kg) can also be administered IV as soon as possible but whether it will be of use or not is debateable.

no severe changes in the cardiopulmonary systems. Your attention can now be moved to correcting other physiological abnormalities if they exist; pour copious amounts of water over hyperthermic animals etc. Then the wound can be addressed with a focus on cleaning the wound and covering it appropriately (see the wound treatment section below). An appropriate antibiotic (e.g. Florfenicol – Nuflor at 20mg/kg IM, no more than 10mls per injection site - extra-label use!) should be administered and the dart wound site should be cleaned and treated with a “dry cow intra-mammary treatment” (e.g. Special Formula 17900-Forte). Non-steroidal anti-inflammatory drugs are **contra-indicated** in these hypovolaemic and myoglobinaemic animals. However, analgesia for these animals should not be neglected, as they will become hyperalgesic when the opioid antagonist is administered. We suggested that lignocaine or bupivacaine should be infiltrated around the base of the horn or an infra-orbital block performed (20mls lignocaine per side). The analgesic effect, although only of short duration, will hopefully reduce distress in the first few hours after the animal is woken up. Placement of a tracking foot collar, on the least compromised limb, will help with monitoring and locating this animal for future treatments.

As soon as a large amount of fluids have been administered, and wound preparations are complete, gently pump and massage the limbs to ensure adequate blood has perfused them before the animal is woken up. Place the animal in sternal recumbency and move all equipment and personnel to a distance far enough not to cause a disturbance to the recovering animal. Administer naltrexone (200mg IV, note the absorption of IM injections may be severely delayed in these cases) and leave the animal to recover on its own without any disturbance. The recovery may take some time and the animal should not be aided with prodding or any other means; stress caused at this time may be detrimental. If the animal is not able to stand after two hours euthanasia should be considered.



Rock art, etching of a black rhino, Twyelfontein, Namibia



List of contacts: SAPS, DEA EMI's, State prosecutors etc.

Mpumulanga

Jean de Beer - 083 628 1827

Adv Isabet Erwee (State prosecutor) – 082 552 2582

Limpopo

Riaan de Jager - 083 627 5991

Mr Dion Lamminga (State prosecutor) - 084 261 2906

Gauteng

Kallie Booysen - 073 305 0161

North West

Rusty Hustler - 083 469 3242

Adv Antoinette Ferreira (State prosecutor) - 051 410 6083

Free State

Werner Boing - 083 400 6595

Eastern Cape

Jaap Pienaar – 0828531844

Western Cape

Paul Guldenhuis - 082 551 8312

KZN

Rod Potter - 082 772 8343

Northern Cape

Pieter van Niekerk - 079 496 4146



Immobilized white rhinoceros

Additional contact details:

SAPS Hawks

012 846 4202

SANParks

Frik Rossouw - 082 908 3056

OP Genetics Laboratory

Dr Cindy Harper - 012 529 8240

Rhino Survival Research

Dr Jacques du Preez – 072 402 3126

Dr Gerhard Steenkamp – 012 529 8276



Initial wound treatment and preparation

A cursory evaluation of the animal should be done to inspect obvious lesions. The following lesions would warrant immediate euthanasia:

1. Mandible fracture
2. Fracture of any long bones
3. Facial trauma so low down that the nerve supply to the lips are severed (at this point in time this level is not precisely known but can be estimated)

4. Severed gastrocnemius tendons bilaterally. With **unilateral** gastrocnemius injury, a fibreglass cast should be applied to include the foot to approximately 20 cm above the hock. An aluminium splint should be incorporated cranially and caudally to strengthen the cast. It is important that a cast is applied before the animal is woken up! Once the animal is up, the forces on the injured tendon are too much and the tendon may rupture further. (At this stage we are not certain if this will work, but it is worth a try and better than leaving the leg as is).
5. Any deep penetrating thoracic or abdominal wounds

Initial approach to facial wounds:

1. Stop any haemorrhage.
2. Take photos of the wound with a tape measure included so that you are able to determine the length and width of the wound.
3. A local infra-orbital block with lignocaine (alone or in combination with morphine) can be done to relieve pain. We have used 20 ml of Lignocaine (1% solution) at each site. (The exact placement of the needle will be published later in 2014. Please contact us in the meantime for advice).
4. Clean the wound with clean water. Do not cause further damage to the wound by using cytotoxic agents (hydrogen peroxide, chlorhexidine), desiccating agents (acriflavine glycerine) or covering it with agents like Stockholm tar.
5. Ideally the wound should be covered with a Zinc Calcium – Alginate dressing (Curasorb® Covidien). This dressing will form a gel to cover the defect, has antibacterial properties and promotes haemostasis. This product can be applied quickly and liberally and should be pushed into opened paranasal sinuses.
6. Keeping the facial wound covered and the dressing in place is difficult. You may either try covering it with bandages which can then be sutured onto the nasal skin, or you can apply layers of fibreglass casting material over the wound dressings, and then suture this onto the sides of the nasal skin. This covering should stay on until your next immobilization and treatment 48 hours later.
7. Other wounds (e.g. gunshot wounds, hack wounds or snare wounds) should be flushed copiously with normal tap water, cleaned and dressed. Because it is often too difficult to bandage these wounds dress the wound with an appropriate ointments or cream such as Flamazine®, L-Mesitran® (Honey), F10® ointment or other antibacterial products. You may also try a product called Kerlix AMD®, which looks like a crepe bandage but is impregnated with an antiseptic similar to chlorhexidine. This bandage may be wetted, and folded into any “cavity”, especially in deep cavities on the back. It serves to kill bacteria in the wound, and protects the wound from further contamination.

Do not forget to evaluate the eyes! More often than not if the rhino has been in lateral recumbency the bottom eye will be damaged and needs evaluation and treatment (Also photograph these eyes).

8. **Ambulatory rhino found with their horns hacked off.** Occasionally the rhino with its horns hacked off is only found after it has emerged from the opioid narcosis, and is already ambulatory. The decision then needs to be made whether to take the risk of re-darting the animal and treating as written above, or should the veterinarian re-assess the animal after 48 hours. The decision will depend on the severity of the facial trauma and presence of severe haemorrhage, as well as, the habitus, mobility and gait of the animal. It is essential to attempt to obtain an idea of the time elapsed since the rhino was immobilized and its horns hacked off. This will make the decision more obvious.



What to do with the blood samples and the Rhino Survival Research project.

The analysis of blood samples from survivors of poaching events is key for us to understand the various physiological alterations that these animals undergo, and to identify blood parameters that can serve to either prognosticate or to monitor response to treatment. For this purpose, the “Rhino Survival Research” project was started, and it is therefore important to collect blood every time you immobilize and treat an injured rhino. However, it is essential that the blood samples are handled and processed correctly in order to get the most accurate results from them. For this purpose, it would be best to contact the primary researcher (Jacques du Preez – 072 402 3126) and arrange with him to attend to the rhino with you in order for him to collect the samples himself. If this is not possible, please follow the procedures described below.

The following blood samples should be collected in this order and processed as follows:

1. Serum (red) x 2:

Various serum biochemistry assays will be performed on the serum which will include total serum protein, albumin, CK, AST, creatinine, urea, lactate, Na and K. It is critical that the serum is removed from the clot as soon as possible and stored in a refrigerator or frozen (preferred). This is done after placing the sample in a centrifuge for at least 8 minutes at 4000 rpm. The reason is that several of the analytes can be found in high concentrations in the red blood cells, and will start to leak into the serum if left on the clot for too long. This will result in inaccurate data that will skew the research results.

2. EDTA (purple) x 1:

A complete blood count (CBC) will be performed which will include a blood smear evaluation. Due to the expected delays in getting these samples to the Clinical Pathology laboratory at Onderstepoort, 2 thin blood smears should be made of the sample, as well as 2 peripheral blood smears, and left unfixed and unstained. The smears should be sent together with the sample to the laboratory.

3. Heparin (green) x 2:

If the samples will not reach the laboratory within 24 hours it will be ideal to separate the plasma from the red cells, and refrigerate or freeze the plasma.

4. Fluoride oxalate (grey) x 1

5. Citrate (light blue) x 1

All samples should be sent to the Clinical Pathology Laboratory at Onderstepoort. The cost of all the assays performed will be covered by the research grant and the results will be made available to the attending veterinarian as soon as possible.

Samples should be sent for the attention of:
Attention: Prof Amelia Goddard
Clinical Pathology Laboratory
Onderstepoort Veterinary Academic Hospital, R3-11
Old Soutpan Road
Onderstepoort, Pretoria
0110

Important note: Please include a detailed clinical description for record purposes. The latter should include your contact details (incl. fax/e-mail in order to send results), identification of the animal (age, sex, microchip/ear notch nr) and a description of the clinical state of the animal. The primary researcher (Jacques du Preez) will then contact you to get all other relevant details that might be needed still.

We are also in the process of sourcing either a car battery- or hand operated centrifuge to ease the work while out in the field. We will keep you posted.

To aid clinicians in the field the use of a handheld lactate meter has been evaluated and validated for use in rhino. From this study we know that lactate in immobilised white rhino is in the region of 15 – 20 mmol/l. To this day we have received very little blood from poached individuals that have either survived or died, therefore it is impossible at this point in time to give an accurate value of lactate, or any other blood parameter, that can be used to determine a prognosis. New research in 2014 hopes to address this important study and therefore we implore you to please send blood samples from injured animals every time you treat them.

From one animal that died in 2012 we know the lactate was above 5000 mmol/l. It is hoped that we can validate the use of lactate as a prognostic marker to give clinicians a relevant animal side test to help prognosticate. At the moment Gerhard Steenkamp (gerhard.steenkamp@up.ac.za) still has a few lactate metres available for those individuals who can make use of them (for free) and would like help with this study. Please contact him or Jacques du Preez (072 402 3126 or jacques.dupreez@tuks.co.za) if you are interested.



8. Dead Rhinos and Forensics

A full forensic post-mortem should be performed on any dead rhino, one that dies during treatment or needs to be euthanased. If there is a live calf present, this will have to be dealt with first. Small calves can be manually restrained and hand injected with a tranquiliser (azaperone, Stresnil®). Large calves will need to be darted before they can be handled. The decision will then need to be made whether the calves are to be released with their dams after opioid reversal, or will these calves be taken to a reputable rhino rehabilitation centre where they can be integrated into a rhino group.

With the current upsurge in syndicated rhino poaching in Southern Africa, when a dead rhino is found, the circumstances of the death needs to be thoroughly investigated, be it in a National Park, Provincial Reserve or private ranch/farm. All such mortality events should be treated as a “crime scene” until to the contrary. It is important that, where possible, the investigation is done by a team of specialists, including law enforcement officials and the investigating veterinarian.



8.1 The Crime Scene



This includes the immediate site of the rhino carcass and surrounding area. It is essential that even before any Post Mortem examination of the victim begins, the crime scene should be secured and thoroughly inspected in order to locate and identify any “trace evidence” that may be present on site, and may link the perpetrators to the crime.

Trace evidence may include:

- 1) Firearms, cartridges, darts, bullets, bullet fragments, and cartridge cases.
- 2) Suspicious or personal items found at the scene such as cell phones, note books, scraps of paper, cigarette packages or “stompies”, items of clothing (especially hats, caps or handkerchiefs), tools such as axes, saws or knives.
- 3) Foot prints, vehicle tyre tracks, helicopter skid marks and indicators of rotor downdraft. It is important to establish whether the poachers were on foot, their approach and departure



It is extremely important to limit the number of persons who approach the carcass, in order to reduce disturbance of the surroundings.

directions, vehicle approach and departure directions or whether a helicopter was used.

It may be useful to mark off the “crime scene” and surrounds with “danger/warning tape”, and for the investigating team to scour the area by walking pre-determined transects.

All trace evidence found should be photographed *in situ* with the camera “date and time mode” activated. Where feasible “trace evidence” should be collected and sealed in appropriate containers in

the presence of a law enforcement official. A “**chain of custody**” of the collected trace evidence and photo documentation must be established and secure.

Prior to starting with the post mortem examination, the veterinarian should attempt to establish:

- 1) whether the animal died in its tracks or was it wounded and did it run some distance before expiring (tracks - running, walking, staggering, fell down and got up again, blood trails etc).
- 2) the approximate time of death
- 3) if the rhino died in its tracks, attempt to establish the trajectory of the shots from bullet entrance and exit wounds. The rhino should be rolled over to establish number of gunshot wounds and the trajectory angles, and to see whether the bullets exited. If the rhino is lying in lateral recumbency, it may also be lying on a dart. Establishing trajectory angles is important for finding spent cartridge cases. Spent cartridge cases can be matched to a rifle's chamber, extractor and firing pin.

Once the crime scene has been secured, and law enforcement personnel are satisfied that most trace evidence has been collected, then the veterinarian can proceed with his detailed forensic necropsy.



Equipment needed for a detailed forensic necropsy on a rhino

These include:

- 1) Several sharp knives of differing sizes and blade conformation.
- 2) A sharpening steel.
- 3) A sharp axe or bone saw and strong lopper..
- 4) A strong rope or belting material.
- 5) Several plastic or metal probes.
- 6) Scalpel, forceps, scissors and a cutting board
- 7) A well calibrated metal detector is very useful for finding bullets in large pachyderms. Always keep a bullet sized metal object available for setting sensitivity of the detector.
- 8) Forensic kit for specimen taking, which includes blood tubes, bleeding needle and hub, specimen bottles, gloves, syringes, drill bit, zip-lock plastic bag, SAP numbered forensic trace evidence bags. These kits are available from Dr. Cindy Harper at the Veterinary Genetics Laboratory at Onderstepoort.
- 9) If the manpower available is inadequate, a car winch or hydraulic hoist is very useful



Gunshot wounds and wound channels

The detailed examination of a gunshot wound may answer some of the following questions:

- Type of weapon used.
- Number and type of projectile (calibre, construction and bullet weight)
- Position of shooter relative to victim (trajectory)

- Lethality and incapacitation caused by wound
- Age of wound
- Every rifled firearms barrel has its own unique rifling imprint = fingerprint. The recovered projectile (bullet) may aid in identifying the weapon used. It is possible to match a bullet to the weapon that fired it and this evidence is admissible in court.

Bullet wounds may be single and cryptic or multiple and obvious. If an animal drops dead in its tracks from a single shot, there may be little or no blood visible at the wound site. Exit wounds generally bleed more profusely than entrance wounds. Animals that have run a short distance after being shot will generally have more blood oozing from the bullet wounds. Check the carcass for both entrance and exit wounds, and roll the carcass over if possible. As you proceed with the examination, use plastic or metal probes to follow the wound channel. The wound channel is characterised by linear rupture of soft tissues with haemorrhage, fracture and possible fragmentation of long bones, and penetration holes in flat bones. It is important to try and locate the bullet and collect it as “trace evidence”.

Animals that were criminally darted with lethal drugs or an opioid and have died and had their horns removed are a more difficult challenge, because there are no bullet wounds and dart needle punctures are very cryptic. One may need to remove the skin at all common dart sites and look for soft tissue localised haemorrhages. If such a dart site is located, collect tissue from the skin subcutaneous and muscular tissue at the dart site, place in a container and freeze. It is possible to detect minuscule amounts of opioid residues by specialised chromatographic techniques (Jockey Club laboratory). If the dart is found on the ground or still in the animal, remember that darts are ideal objects for fingerprint analysis so if there is a dart in the rhino take pictures and preserve the dart in a forensic bag. Handle the dart in a way so as not to destroy any prints. Don't handle it by the barrel or the rear flight piece.



Necropsy Technique for Poached rhinos

If the prime objective is to locate the projectiles (bullets) for forensic purposes, the technique will be influenced by the anatomical position of the entrance and exit bullet wounds. If the intent is to determine the actual cause and mechanism of death, a more detailed examination of all organs is required. If there are obvious bullet wounds, first scan the whole carcass with a metal detector. The bullet may be lodged superficially under the skin on the side opposite to the entrance wound. It is also important to collect appropriate DNA samples and place them in the containers supplied in your forensic kit bag. To open a rhino carcass, the following technique has been used successfully:

- Reflect the upper forelimb and remove by dissecting loose from the rib cage.
- Reflect the upper hind limb by cutting through the adductor muscles and disarticulating the hip joint.
- Make a midline ventral skin incision, and dissect the skin panels covering the thorax and abdomen loose from the underlying muscles

- Incise the abdominal muscles along the contour behind the costal arch and then through the ventral midline
- Incise the diaphragm.
- Remove the ribs on the upper side.
- Now all abdominal and thoracic organs should be visible.
- After opening the carcass, scan each limb as it is removed.
- Scan each large chunk of tissue that is removed.
- Follow the wound channel as far as possible.
- Scan each organ as it is removed. Scan horns if present.
- Also scan the ground around the carcass, especially with old carcasses that been heavily utilised by scavengers.
- Photograph each pathological finding with camera set in the date and time mode.



Common problems with metal detectors

- Batteries are low.
- Incorrect sensitivity selection – calibrate with a bullet or suitable small metal object
- If the surrounding geology is iron rich (e.g. riolites or gneiss), the heavy background signal makes the metal detector almost useless.

After the Post mortem has been concluded, it is important that a “**Chain of Custody**” is maintained for:

- All “trace evidence” in appropriately marked containers sealed in the presence of a law enforcement official.
- All photo documentation
- All evidence and reports that may be used in litigation.



Forensic Necropsy Report

After completing the detailed necropsy, the attending veterinarian should produce a Forensic Necropsy Report which:

- describes all external and internal lesions found and photographed.
- documents all items/trace evidence collected from the carcass and photographed.
- documents all tissues collected for laboratory analysis
- lists significant findings in order of importance
- Indicates a preliminary morphological diagnosis.

Once the laboratory results (e.g. poison identification, opioid confirmation) have been received, then these can also be included into the report, together with a final aetiological diagnosis.

Acknowledgements

Many thanks to the following people for their valuable advice and inputs: Dr Richard Burroughs, Dr Catriona Lyle, Prof Frik Stegmann, Dr Peter Caldwell and Dr Colin Mitchell.

Table 1. Normal clinical parameters in unrestrained standing white rhinoceros (Citino et al. 2007)

Physiological parameter	Mean	Min	Max
Heart rate (beats.min ⁻¹)	39	32	42
Respiratory rate (breaths.min ⁻¹)	19	16	23
Indirect systolic pressure (mmHg)	160	146	183
Indirect mean pressure (mmHg)	124	108	135
Indirect diastolic pressure (mmHg)	104	88	117
Rectal temperature (°C)	36.8	36.6	37.2

Summary Sheets

For ease of use we have summarized the details above into 4 sheets which you can print out and use in the field (lamination suggested)

Sheet 1: Summary of initial evaluation, decision-making and treatment

Sheet 2: Summary of wound treatment procedure

Sheet 3: Summary of crime scene evaluation and forensic post mortem

Sheet 4: Summary of blood samples needed for Rhino Survival Research