

IMPORTATION OF SOUTHERN WHITE RHINOCEROS FROM SINGAPORE

Jennifer McNamara, Virginia Zoological Park, Jennifer.mcnamara@norfolk.gov

In April of 2017 the Virginia Zoo collaborated with the Singapore Zoo on an importation of 0.2 white rhinos. These females will be an important addition to the diverse collection of animals housed at the Virginia Zoo. The Virginia Zoo has previously housed white rhinos but these young females will be in a newly renovated enclosure in the hopes to have a breeding group in the coming years.

TEAM NEPALORADO - A RHINO COMMUNITY

Dave Johnson, Denver Zoo, rockymtnguy40@yahoo.com

Rhinos are some of the most endangered large mammals left on our planet, and the population of the greater one-horned rhino and black rhino together is not even ten thousand individuals. We have both of these species at our zoo in Denver and being a zookeeper working on the pachyderm team, I wanted to make a difference in both of their conservation efforts. I wanted to start a movement with our local people, to educate them, and most importantly, get them involved on a global scale. I started to take small groups over to Nepal to help with their conservation efforts back in 2010. Annually we travel over with our Team Nepalorado, which is a fusion of cultures in the name of conservation. This has led to the creation of a non-profit and the subsequent addition of work in Tanzania too. In addition, I write children's books and now teach in the local area on my days off. I have been to Nepal eight times. Chitwan National Park used to have 10-12 poaching incidents a year, and now they celebrate years without a single rhino lost. Our community is vibrant, passionate, and making a huge difference in so many ways.

RHINOPLASTY: MONITORING OF A TUMOR GROWTH THROUGH VOLUNTARY RADIOGRAPH BEHAVIOR

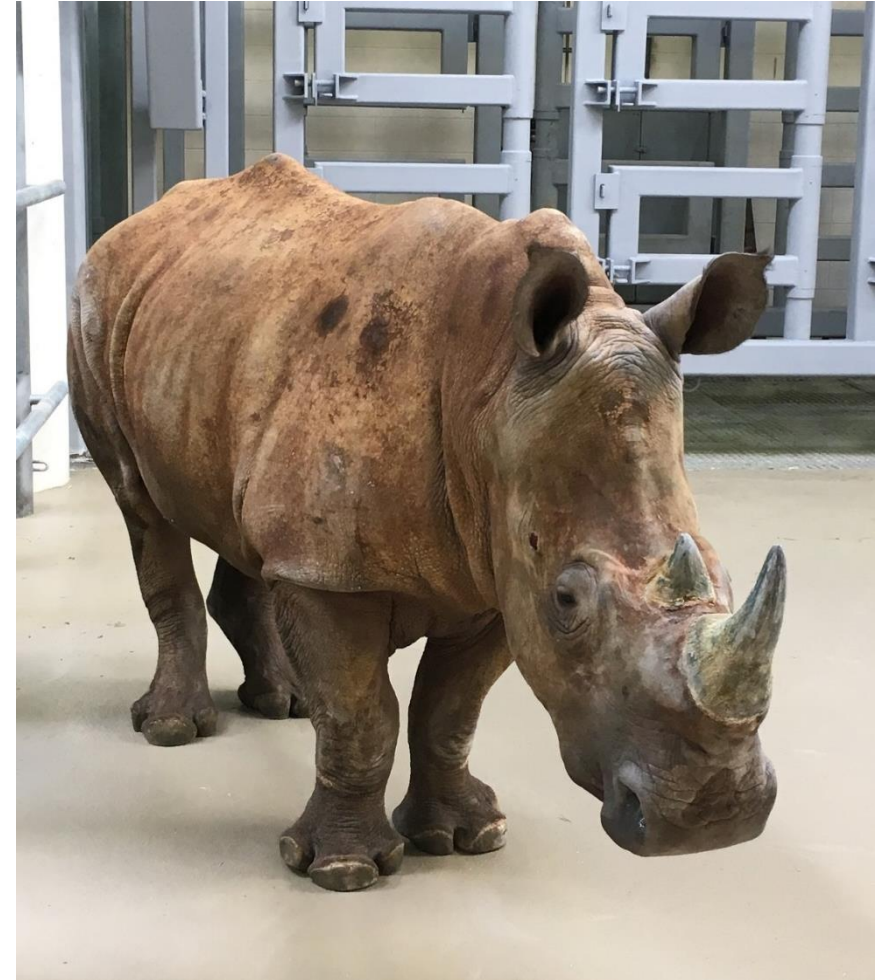David Backus, Lion Country Safari, dbackus28@gmail.com

Lissa, a Southern white rhinoceros living at Lion Country Safari in Loxahatchee, FL, is trained to allow staff members to take radiographs so her health can be monitored. Lissa originally presented with a small abscess at the base of her primary horn and after treatments were unsuccessful, the decision was made to immobilize her and investigate the abscess. Radiographs taken during the immobilization showed a mass occupying a large portion of Lissa's primary horn. The mass was determined cancerous and the primary horn, along with the tumor, had to be removed and Lissa was treated for cancer. During treatment, it became apparent that the area had to be monitored with the use of radiographs because of the possibility of tumor regrowth and the possibility it could spread to Lissa's skull and cause complications. The possibility for bone infection, osteomyelitis, was also a concern increasing the desire of our vet staff to take regular radiographs of Lissa's skull. In order to reduce the number of immobilizations necessary, staff agreed that the best way would be to train Lissa to voluntarily stand while radiographs were being taken. Through positive reinforcement Lissa was first target trained to touch a stick with the end of her lips. After some modifications to the chute she was trained to stick her head out the front of the chute and a hold behavior was trained. Next, the task of desensitizing Lissa to the radiograph equipment needed to be accomplished. Not wanting to put the expensive radiograph equipment in close proximity to a moving rhino head, mock equipment was created. After training Lissa to hold her head still while the mock equipment was used to fake taking radiographs, the real equipment was introduced. Once the behavior was established we could take radiograph whenever necessary and monitor the tumor's growth and provide better health care for a rhinoceros recovering from cancer. My talk will detail the steps used in training a voluntary radiograph behavior in a southern white rhinoceros. This was a unique medical case; we could not find any other white rhinoceros having been treated for a mass in a horn. We found two greater one horn rhinos with masses in the horn and a white rhino with a sarcoma in the leg. I will also briefly include the steps used for treatment both before and after the removal of the tumor.

Rhino move from
the Singapore Zoo
to Virginia Zoo

Jennifer McNamara
Africa Lead





2 Females imported from Singapore to Virginia on April 8, 2017

ZINA DOB 12/23/13

BORA DOB 4/27/13




































































Indo-Pacific Gecko
