

OSTEOPATHOLOGY IN THE FEET OF RHINOCEROSSES: LESION TYPE AND DISTRIBUTION

Sophie Regnault, B.Vet. Med. (Hons), Robert Hermes, D.V.M., Ph.D., Thomas Hildebrandt, D.V.M., Ph.D., John Hutchinson, B.Sc., Ph.D., and Renate Weller, Dr. med. vet., Ph.D.

Abstract: An estimated 1,170 white (*Ceratotherium simum*), black (*Diceros bicornis*), greater one-horned (*Rhinoceros unicornis*), and Sumatran (*Dicerorhinus sumatrensis*) rhinoceroses are kept in captivity worldwide, where they are a popular public attraction and serve important roles in education and conservation. Rhinoceroses in captivity are reportedly affected by a variety of foot conditions, including abscesses, nail cracking, and pododermatitis, but there are few studies reporting associated bony pathology in these species. This study aimed to describe osteopathology in rhinoceros feet and identify normal and abnormal osteologic features of rhinoceros feet. The metacarpal-tarsal and phalangeal bones from 81 feet (67 skeletal specimens and 14 cadaveric feet), derived from 27 rhinoceroses of various species, were evaluated in the study (1 black, 11 white, 2 greater one-horned, 3 Javan, 9 Sumatran, and 1 unknown). Bones were examined visually (skeletal specimens) or by computed tomography (cadaver specimens) for evidence of bony lesions. Of the 27 rhinoceroses examined, 22 showed some degree of bone pathology in at least one limb. Six broad categories of pathologic change were identified, with numbers in parentheses representing numbers of rhinoceroses with lesions in at least one limb/number of rhinoceroses examined: enthesopathy (20/27), osteoarthritis (15/27), pathologic bone remodeling (12/27), osteitis-osteomyelitis (3/27), fracture (3/8), and subluxation (3/8). The frequency of pathologic changes in fore- and hind limbs was not significantly different. Most (91%) enthesopathies were observed on the proximal phalanges of the digits, and osteoarthritis was most common in the distal interphalangeal joints of the medial and lateral digits (32 and 26%, respectively). In addition to the pathology described, all examined rhinoceroses also had multiple small surface lucencies in the distal limb bones as an apparently normal anatomic feature. This study is an important first step in identifying both normal and pathologic features of rhinoceros feet and hopefully will thereby contribute to the improved knowledge and care of these species.

Key words: Bone, foot, pathology, remodeling, rhinoceros, joint.

INTRODUCTION

Within the group Perissodactyla (odd-toed ungulates), there are five distinct species of rhinoceros: white (*Ceratotherium simum*), black (*Diceros bicornis*), Sumatran (*Dicerorhinus sumatrensis*), Javan (*Rhinoceros sondaicus*), and greater one-horned (*Rhinoceros unicornis*). All five species are listed on the International Union for the Conservation of Nature Red List of threatened species, at varying levels of vulnerability. Four of the five species are kept in captivity, where they are not only a popular zoo or safari park attraction but also fulfill important roles in education and conservation. These captive individuals may only be a small proportion of the total worldwide population (between 0 and 7.2%, and potentially up to 10%, depending on species and figures used),^{6,7,11,23,26–28} but they may arguably

be an important reservoir in scenarios where reintroduction becomes viable and necessary.²¹

Pathologic conditions of the distal limb can become very problematic within captive populations. As with any disease, there is potential for compromised welfare, but due to the weight and undomesticated nature of rhinoceroses, diseases of the feet add an understandably challenging aspect to their management. Treatment can sometimes be life-endangering for the animals involved, because some diagnostics may require the use of anesthesia, and chronic, nonresolving, painful conditions may ultimately end up warranting euthanasia.^{14,16} The association between lameness and reduced fertility is well recognized in cattle,¹ and it could be speculated that, as a fellow ungulate, foot disease in captive rhinoceroses may similarly affect fertility.

Lesions of the soft tissues, including the foot pad and nails, have been well documented in some of the commonly kept rhinoceros species. Laminitis, pododermatitis (infection of the foot), and coronary band abscesses have been reported in all rhinoceros species.¹¹ More than one fifth of captive greater one-horned rhinoceroses in America and Europe are affected by chronic foot

From the Royal Veterinary College, Hawkshead Lane, North Mymms, Hatfield, Hertfordshire, AL9 7TA, United Kingdom (Regnault, Weller, Hutchinson); and the Leibniz Institute for Zoo and Wildlife Research, Alfred-Kowalke-Straße 7, 10315 Berlin, Germany (Hermes, Hildebrandt). Correspondence should be directed to Dr. Regnault (sregnault@rvc.ac.uk).

Table 1. Breakdown of rhinoceros foot specimens examined in this study.

Species	No. of feet examined	No. of rhinos	Specific limbs examined ^a					No. of complete/incomplete feet	Provenance (zoo/museum)	Source		
			RF	LF	RH	LH	Unknown			Wild	Captive	Unknown
Black	4	1	1	1	1	1	0	4/0	0/4	0	0	4
White	28	11	6	6	8	7	1	25/3	13/15	4	13	11
Greater one-horned	5	2	2	1	1	1	0	5/0	1/4	0	1	4
Javan	11	3	2	2	2	1	4	7/4	0/11	0	0	11
Sumatran	31	9	6	6	7	7	5	22/9	0/31	0	0	31
Unknown	2	1	1	0	1	0	0	0/2	0/2	0	0	2
Total	81	27	18	16	20	17	10	63/18	14/67	4	14	63

^a RF, right fore; LF, left fore; RH, right hind; LH, left hind.

disease (CFD),¹⁵ a condition characterized by fissuring and separation of the foot pad from the middle toe, classically occurring with hoof overgrowth of this digit and hyperplastic tissue growth between the toes. Measures designed to improve rhinoceros welfare in other ways (e.g., natural ground, which is less abrasive but more difficult to keep clean than concrete flooring, or leaving territory-marking dung piles intact to reduce stress¹⁶) mean that the risk of infection is always present once the primary defense barrier, the skin, has been breached, and infections of the feet are common. Once a crack is present, it does not appear difficult for CFD to become complicated by soft tissue (or even bone) infections.^{15,17} Ulceration and deep fissuring of the soft foot pad also can result from penetrative trauma or unfavorable conditions underfoot (e.g., abrasive, continuously damp, or urine-soaked floors).^{16,18} Vertical and

horizontal cracking of the nails is seen in almost 40% of captive greater one-horned rhinoceroses kept in Europe, and causes are thought to include excessive abrasion of the hoof, trauma, laminitis, nutritional disorders, and other systemic illness.^{16,17} Although interdigital granulomas and papillomas have been most frequently observed in black rhinoceroses, they also feature in captive white and greater one-horned rhinoceroses.^{11,18}

Degenerative arthritis can develop in older animals or after trauma, although it appears to be less common in greater one-horned rhinoceroses.^{12,16} Except for the description of osteoarthritis (OA),^{16,25} there is much less information regarding bony pathologic changes in the feet of rhinoceroses. In other large mammalian species, for example, horses and cattle, bone pathologies are well described.^{1,3} In elephants, another megaherbivore with prominent presence in captivity, a

Table 2. Pathology categorization scheme used in the study, modified from a similar scheme used in elephants.

Diagnosis	Changes observed
Calcifications	Mineral opacities within soft tissue
Osteomyelitis-osteitis	Disruption of normal bone pattern, mottled appearance, multiple lucencies, loss of parts of bone, destruction of normal bone outline, periosteal new bone formation
Enthesopathies	Discrete new bone formation at attachment sites of tendons and ligaments
Cyst-like lesions	Well-defined lucencies (with sclerotic rim)
Fractures	Sclerotic linear areas, may be with new bone formation at bone surface (old) Linear lucency (acute)
Degenerative arthritis-osteoarthritis	Discrete new bone at periarticular surface, subchondral bone sclerosis, narrowing or obliteration of joint space, subchondral lysis, widening of joint space
Infectious arthritis	Florid new bone formation at periarticular surface, subchondral bone lysis, widening of joint space, subchondral bone sclerosis, narrowing or obliteration of joint space
Remodeling	Pathologic exaggeration of vascular channels and synovial fossae, sometimes into deep excavations in the bone
Subluxation	Loss of articular surface contact between the bones forming a joint

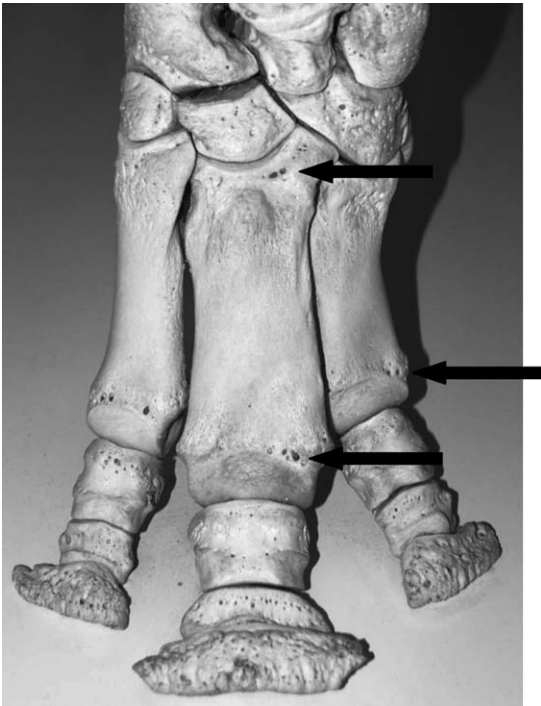


Figure 1. Left manus of a white rhinoceros (*Ceratotherium simum*), in cranial view, highlighting some of the lucencies (normal bony excavations or holes that correspond to radiographic lucencies, black arrows) observed in many museum osteologic specimens and showing their typical appearance and distribution.

variety of bony foot lesions have been documented, including OA, septic osteitis and arthritis, ankylosis, and metabolic bone disease.¹⁰ Factors such as weight, activity level, environmental conditions, trauma, and nutritional status of the animal are presumed to play various key roles in the progression of these diseases, and one would anticipate that the limbs of rhinoceroses experience similar etiologic stressors and thus would be similarly susceptible. Yet, there are only two published cases of osteomyelitis in rhinos,^{8,13} and these cases seem to be the limit of documented rhinoceros osteopathology.

Unlike most soft tissue conditions of the foot, bone pathology is not externally apparent. Aside from making it more difficult to diagnose and treat, this might be the reason why information on bone pathology in rhinoceroses is rare. New findings in this area may have implications for future management of these species in captivity.

Across the five species, distal limb anatomy is generally conserved; all have stout “mediportal” legs⁴ to support their weight, and all walk on three

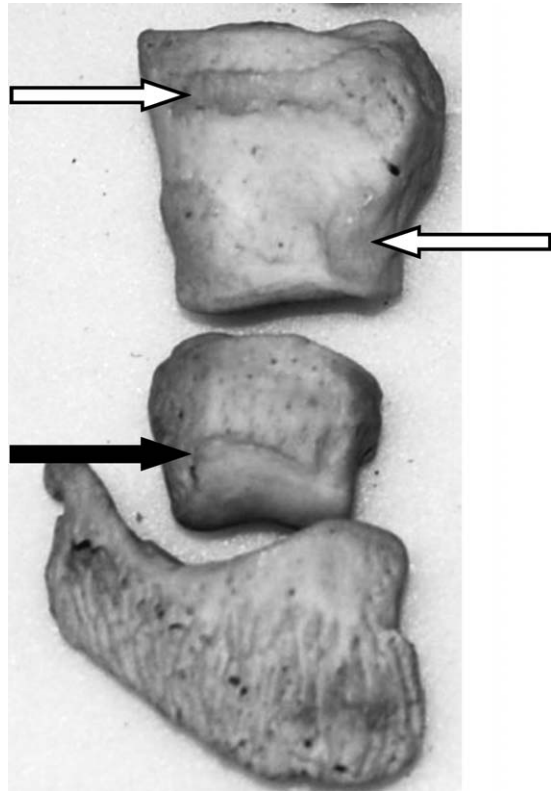


Figure 2. Distal, middle, and proximal phalanges of digit II of a Sumatran rhinoceros (*Dicerorhinus sumatrensis*), in cranial view. Note the formation of discrete new bone at likely joint capsule and ligament attachment sites on the proximal phalanx (enthesophytes, unfilled arrows), and at the distal articular margin of the middle phalanx (osteophyte, filled arrow), indicating osteoarthritis of the distal interphalangeal joint.

toes—digits II, III, and IV—that terminate in a hoof capsule. The middle and caudal regions of the foot are cushioned by a pad composed primarily of fatty and fibrous tissue.^{14,20} Digit III is always centrally located and largest, with digits II and IV on the medial and lateral sides, respectively. Each digit comprises a distal, middle, and proximal phalanx that connects to the metacarpal (front foot) or metatarsal (hind foot) bone. In all species, each of the metacarpal and metatarsal bones has an associated pair of sesamoid bones, called the proximal sesamoid bones, on the palmar or plantar aspect.

An apparent interspecific difference in skeletal anatomy appears to be the variable presence of another sesamoid bone in addition to the two proximal sesamoids of each digit, called the distal sesamoid bone, found between the distal and middle phalanges on the palmar or plantar aspect



Figure 3. Middle and proximal phalanges of digit IV of a right manus belonging to a white rhinoceros (*Ceratotherium simum*), in oblique proximal view. Note the loss of articular surface integrity on each bone and roughened appearance, indicating an advanced grade of osteoarthritis present in the proximal interphalangeal joint.

of the distal interphalangeal joint. In horses, a related species also belonging to Perissodactyla, it is sometimes called the navicular bone. The presence of the distal sesamoid bone as a normal anatomic feature in greater one-horned rhinoceroses is acknowledged in the literature,^{2,14} but not mentioned for the other rhinoceros species. The overall aim of this study was to describe normal and abnormal osteologic features in rhinoceros feet, identifying common lesion types and their distribution, and to determine predilection sites for pathology, in terms of limb, digit, or bone.

MATERIALS AND METHODS

The bones of 81 rhinoceros feet were examined in this study, originating from 27 individual rhinoceroses (see Table 1 for a full breakdown of foot specimens). Within this study, a "complete" foot specimen was considered to consist of three distal phalanges, three middle phalanges, three proximal phalanges, three metacarpals-metatarsals, and three pairs of proximal sesamoids, numbering 18 bones in all. Although examined and noted where present, the distal sesamoid bones were not explicitly recorded for pathology, due to the difficulty in determining whether these bones were missing or were truly absent from specimens. Most of the feet were complete—63 of 81 feet had all bones present. In the 18 incomplete feet (belonging to eight individuals total), there was an average of 8.7 bones present (of a possible 18) per foot. Ten feet/three rhinoceroses had relatively more bones missing (an average of only 4.1 bones/foot), and eight feet/five rhinoceroses

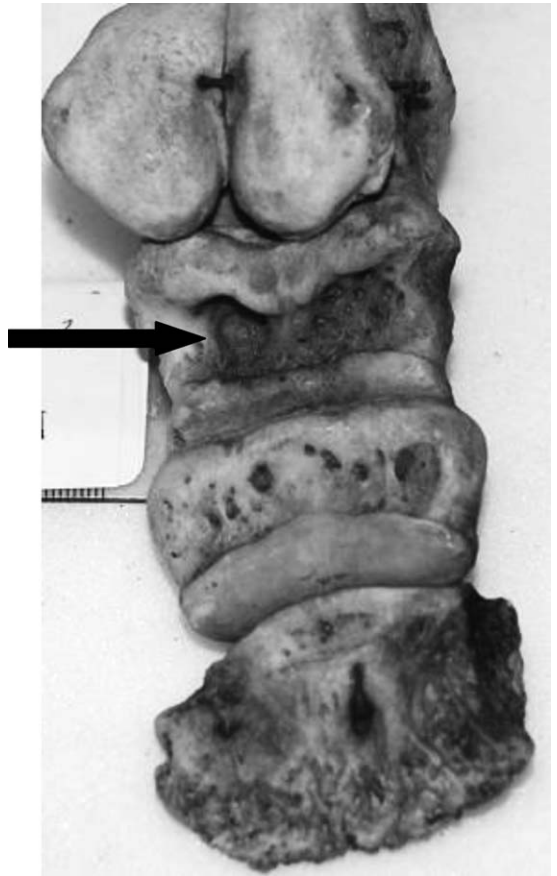


Figure 4. Plantar view of digit III of the left pes from a Sumatran rhinoceros (*Dicerorhinus sumatrensis*), showing pathologic bone remodeling. Note the larger holes and deep bony excavations (black arrow), especially on the proximal phalanx. Anecdotal, these excavations appeared more typically in Sumatran rhino museum specimens than in the other species.

had relatively fewer bones missing (average 14.4 bones/foot). The bones found to be most frequently missing were proximal sesamoids (constituting 43% of all missing bones), followed by distal phalanges (24%), middle phalanges (17%), proximal phalanges (15%), and metacarpal-metatarsal (under 1%).

Almost all bones could be positively identified as belonging to fore- vs. hind and left vs. right feet. The only exceptions were nine of the 10 feet belonging to the three rhinoceroses missing relatively more bones, whose limbs of origin could not be determined, and one foot that could only be identified as from a forelimb (i.e., not clearly left or right). All but one rhinoceros (two feet) were skeletally mature.

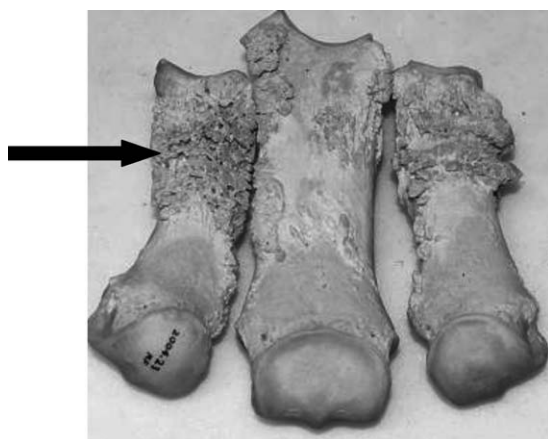


Figure 5. Metacarpal bones of the right manus, in cranial view, belonging to a Sumatran rhinoceros (*Dicerorhinus sumatrensis*), highlighting osteitis affecting these bones (black arrow).

Fourteen whole, frozen cadaveric feet (from eight individual rhinoceroses; seven white and one greater one-horned) were donated from several European zoological institutions, and these feet underwent computed tomography (CT) imaging using a GE Lightspeed 8-detector unit (100 mA, 120 kVp, helical scan, 2.5-mm slice thickness, bone algorithm; GE Healthcare, Polaris Wood, Nightingales Lane, Chalfont St. Giles, HP8 4SP, United Kingdom). Although not the focus of this study, any externally visible soft tissue lesions on the cadaveric specimens also were noted. These lesions were examined along with osteologic specimens, both mounted and not, belonging to the Cambridge University Museum of Zoology (23 feet/seven rhinoceroses), the Oxford Museum of Natural History (seven feet/two rhinoceroses), and the Natural History Museum of London (37 feet/10 rhinoceroses). The anatomic configuration of all specimens was noted, and signs of bony pathology were recorded, including type and location.

There are no published data on the normal osteology of rhinoceros feet to act as a standard with which to compare the foot bone specimens. Hence, in this study, the general principles of osteopathology, largely based on applied knowledge from more commonly examined species (namely, cattle, horses, and elephants), was used. The assessment of specimens was performed together by the senior (RW) and first author (SR) of this paper. Assessment also incorporated modified criteria from an existing scheme first developed for evaluating elephant osteopathology,³⁰ to ensure a high level of objectivity when

Table 3. Breakdown of pathologic lesions in positively identified fore- and hind feet.

	Identified forefeet	Identified hind feet
Total	35	37
Exhibiting pathology	27	26
Enthesiopathy	22	19
Osteoarthritis	16	17
Remodeling	10	9
Osteitis-osteomyelitis	3	0
Fracture	2	1
Subluxation	2	1

evaluating both bone and CT-scanned specimens (Table 2).

The proportion of pathologic lesions exhibited by fore- and hind feet were compared by chi-square testing, when appropriate (i.e., where numbers were large enough to allow for valid statistical comparison). The number of Sumatran and white rhinoceros foot specimens in this study made it permissible to also compare the proportion of pathologic lesions between individuals of these two species with chi-square testing.

RESULTS

Bone anatomy

The distal sesamoid bone, a normal feature of greater one-horned rhinoceros foot anatomy, was absent in all of the white (28 feet/11 rhinoceroses) and black (four feet/one rhinoceros) specimens used in the study, including the CT scan images. Some of the Sumatran (31 feet/nine rhinoceroses) and Javan (11 feet/three rhinoceroses) articulated museum specimens did possess the distal sesamoid bone, but it was not a consistent feature between, or even within, individuals.

All of the rhinoceroses exhibited multiple small, circular, surface bone lucencies in the distal phalanx, around the metaphyseal regions of the middle, proximal, metacarpal, and metatarsal bones and occasionally on the sesamoid bones (Fig. 1). Note that lucency is typically used as a radiographic term; it is used here to refer to both the radiographic lucencies seen on CT as well as the bony excavations that they correspond to in the osteologic specimens.

Pathologic findings and their distribution

Externally visible soft tissue pathology noted on the cadaveric specimens included swelling, congestion, and disruption of the coronary band (three/eight rhinoceroses, all white); both worn

Table 4. Distribution of enthesophytes between the bones of rhinoceros feet. Data are presented as number (percent).^a

	Digit II, medial	Digit III, central	Digit IV, lateral
DP	0 (0)	4 (4)	0 (0)
MP	0 (0)	0 (0)	0 (0)
PP	34 (35)	28 (29)	27 (28)
MC-MT	1 (1)	3 (3)	1 (1)
Total	98 (100)		

^a DP, distal phalanx; MP, middle phalanx; PP, proximal phalanx; MC-MT, metacarpal-metatarsal bone.

(four/eight rhinoceroses, three white and one greater one-horned) and overgrown (one/eight rhinoceroses, white) nails; irregularities, cracking, and erosion or wearing of the footpad (six/eight rhinoceroses, five white and one greater one-horned); an infected solar abscess (one/eight rhinoceroses, white); nail cracks (one/eight rhinoceroses, white); and a missing nail with exposure of the laminae (one/eight rhinoceroses, white).

Six broad categories of pathologic bony change were identified in the study and are presented in descending order of frequency: enthesophyte formation, OA, remodeling, osteitis-osteomyelitis, fracture, and subluxation. Enthesopathy manifests itself as discrete new bone at sites of ligament, tendon, or joint capsule attachment. OA is represented by subchondral bone erosion, sclerosis, and osteophyte formation (Figs. 2, 3). Remodeling refers to bone changes that were reminiscent of the "normal" surface lucencies but remodeled to a pathologic extreme, with widening of the usually small holes and sometimes cavernous excavation of the palmar or plantar bone (Fig. 4). Osteitis refers to inflammation of a bone without a myeloid (marrow) cavity, and osteomyelitis in bones with a myeloid cavity, although the

Table 5. Distribution of osteoarthritis between the joints of the rhinoceros feet. Data are presented as number (percent).^a

	Digit II, medial	Digit III, central	Digit IV, lateral
DIP	21 (32)	5 (8)	17 (26)
PIP	0 (0)	3 (5)	2 (3)
MCP-MTP	5 (8)	5 (8)	7 (11)
Total	65 (100)		

^a DIP, distal interphalangeal joint; PIP, proximal interphalangeal joint; MCP-MTP, metacarpophalangeal-metatarsophalangeal joint.

Table 6. Distribution of bony remodeling between the bones of the rhinoceros feet. Data are presented as number (percent).^a

	Digit II, medial	Digit III, central	Digit IV, lateral
DP	5 (17)	1 (3)	6 (20)
MP	0 (0)	1 (3)	2 (7)
PP	2 (7)	7 (23)	4 (13)
MC/MT	2 (7)	0 (0)	0 (0)
Total	30 (100)		

^a DP, distal phalanx; MP, middle phalanx; PP, proximal phalanx; MC-MT, metacarpal-metatarsal bone.

terms are sometimes used interchangeably. Both appear as a florid proliferative-lytic bony reaction (Fig. 5). Of the 27 rhinoceroses examined, 22 exhibited some degree of bone pathology in at least one limb. This finding can be expressed alternatively as 54 feet of 81 exhibiting some degree of osteopathology.

Table 3 lists the breakdown of pathology between the positively identified fore- and hind feet, which appear equally affected by pathologic change. Chi-square testing found no significant difference between the proportion of overall pathology and no difference in the proportion of enthesopathy between the fore- and hind feet. Other pathology types were less variable between fore- and hind feet (and so would similarly give a statistically insignificant chi-square result), were not numerous enough to allow for valid statistical comparison, or both. Tables 4–7 illustrate the distribution of enthesophyte, osteoarthritis, remodeling, and osteitis-osteomyelitis between the digits, joints, and bones of the feet.

The most commonly observed change was enthesophyte formation (20/27 rhinoceroses or 42/81 feet) (Fig. 2). Ninety-one percent of all observed enthesopathies were in the proximal phalanges. Enthesophytes were typically seen on

Table 7. Distribution of osteitis-osteomyelitis between the bones of the rhinoceros feet. Data are presented as number (percent).^a

	Digit II, medial	Digit III, central	Digit IV, lateral
DP	0 (0)	0 (0)	0 (0)
MP	0 (0)	1 (11)	0 (0)
PP	0 (0)	1 (11)	0 (0)
MC-MT	2 (22)	2 (22)	3 (33)
Total	9 (100)		

^a DP, distal phalanx; MP, middle phalanx; PP, proximal phalanx; MC-MT, metacarpal-metatarsal bone.

the dorsoproximal surface of this bone, along the metaphyseal region and also more distally, bilaterally on the dorsolateral aspects.

OA was the next most frequently observed lesion (15/27 rhinoceroses or 34/81 feet). There appears to be a heavy predilection for OA in the distal interphalangeal joint, accounting for 66% of observed OA lesions. The metacarpophalangeal and metatarsophalangeal joints accounted for 26% of observed OA lesions. Interestingly, although there was no overall difference in OA prevalence between the fore- and hind feet, separately the metacarpophalangeal joint was affected more than four times as often as the metatarsophalangeal joint (22 vs. 5% of all OA observations, respectively). The proximal interphalangeal joint was least affected, comprising 8% of all OA observations.

A proportion (12/27 rhinoceroses or 19/81 feet) of rhinoceroses had remodeling-type changes; this apparently pathologic remodeling was frequently focused over sites of normal surface lucencies.

Osteitis, osteomyelitis, or both were seen in three/27 rhinoceroses or three/81 feet (Fig. 5). All cases in this study were in forefeet. All had some metacarpal involvement, although the number varied: in one animal, all three metacarpals exhibited severe changes, whereas in another animal with equally severe lesions, only the metacarpal of the fourth digit was affected. The worst-affected region (and likely original source) in these three animals varied between animals from middle phalanx to mid-metacarpal to proximal metacarpal.

Fracture and subluxation was only diagnosed in the whole cadaveric feet that underwent CT scanning; these conditions were equally prevalent (both observed in three/eight rhinoceroses or three/14 feet, although not in the same rhinoceroses or feet). The majority (two/three rhinoceroses or two/three feet) of the fractures were small bony fragments visualized on CT close to the distal phalanx of the central digit. The remaining foot belonged to a greater one-horned rhinoceros—one of the osteomyelitis cases described in literature—who experienced an iatrogenic fracture of the central digit middle phalanx during treatment.⁸ In addition to this gross fracturing of the middle phalanx, the rhinoceros also had several other bone fragments around the proximal metacarpal region and another close to the paired sesamoid bones of the central digit.

There were six subluxations in total (in three/eight rhinoceroses or in three/eight feet) ob-

served, all minimally displaced with only partial loss of articular surface contact, and almost all (five/six subluxations) were of the proximal interphalangeal joint.

The proximal sesamoid bones exhibited virtually no obvious pathology, with the only exception being the fracture of one in the central digit in the greater one-horned rhinoceros previously mentioned from the literature with osteomyelitis and iatrogenic fractures. Another rhinoceros had a fused pair of proximal sesamoids in one of its feet, but this condition was not considered pathologic.

White (11) and Sumatran (nine) rhinoceroses, as the most numerous in this study, were compared but found to have no significant difference in the overall prevalence of pathology or in the types of specific pathologic lesion. Anecdotally, however, deep, remodeling-type excavations were seen more characteristically on the plantar surface of the proximal phalanx of Sumatran rhinoceros specimens.

DISCUSSION

In addition to outwardly apparent soft tissue pathologies acknowledged in the literature and exhibited by some of the cadaveric specimens, this study has found that there also exist a variety of osteopathologies in the feet of rhinoceroses. Some of these osteopathologies appear to have been previously unrecognized (e.g., enthesophyte formation, pathologic remodeling), and others are possibly more common than might have been formerly thought (e.g., osteitis-osteomyelitis). Lesion types already cited in the literature, namely, OA and osteomyelitis, were expected, but the recognition of other lesion types also was anticipated. Captive elephants have been observed with many pathologic changes within the distal limb, including roughened and irregular margination, reduction in joint spaces, bone cysts, osteophytes, osteolysis, ankylosis, and bony proliferation.³⁰ The regional analysis of pathology also was inspired by the observation of a bias toward more pathologies in digits III–V in elephants,^{9,19} and an apparent correlation between this biased regional incidence and high pressures on those same toes in elephants.²²

Enthesopathy was the most common type of bony change observed. New bone at sites of soft tissue attachment is thought to reflect the bone's response to large forces through the soft tissues. In horses, this is not necessarily correlated with clinical signs.²⁴ Such forces may be generated in a traumatic event or be more chronic in nature, for example, through altered use of the limb (either

physically due to conformation or functionally due to environment or habit). The detailed soft tissue anatomy of rhinoceros feet has yet to be described in detail; thus, the distribution of enthesophytes is difficult to elucidate. Rhinoceros feet might be analogous to horses' feet, however, in that they may develop enthesophytes at several sites on the proximal phalanx as a result of desmitis of the distal sesamoidean ligaments.³

The apparent pathologic remodeling of bone is challenging to interpret. It may represent responsive remodeling to stress or strain, be a sign of increased synovial pressure, or be a manifestation of nutritional imbalance. Without detailed animal history and a lack of comparable lesions in related species, we can only speculate.

Osteitis-osteomyelitis may be infectious or noninfectious in etiology. It can be a result of a trauma, which may also introduce infection, or spread of inflammation from nearby soft tissue structures.²⁴ The fact that three rhinos of 27 were observed with signs of osteitis indicates that the condition is more common than the number of cases in the published literature suggest, although it must be acknowledged that one of the cases has previously been reported.

The cause of the chip-like fractures in some of the cadaveric feet is likely to be traumatic, especially in the case of the rhinoceros concurrently exhibiting gross iatrogenic fracturing. However, like enthesophytes, the presence of bony fragments in horses may be an incidental finding without the animal exhibiting clinical signs.²⁴

OA is the endpoint of a variety of disease processes as well as being a consequence of normal wear-and-tear use of limbs in such a large and relatively athletic animal. It can be a result of placement of abnormal forces on a stable joint, normal forces on an unstable joint, or conditions in which articular cartilage becomes damaged.²⁴ More than two thirds of observed OA was in the distal interphalangeal joint, indicating that this joint is perhaps more likely to experience large forces, unstable forces, or both over its lifetime. The reasons for this bias of foot bone pathology are unclear because the mechanics of locomotion in rhinoceroses is almost entirely unknown. However, future studies could fill this empirical gap. The distal bones of the feet are the most directly (via the hooves) interacting with the substrate, so it is possible they experience higher stresses, and account for the predilection of OA in the distal interphalangeal (rather than the more proximal) joints. They also are closest to the solar surface and so might be more prone to ascending

infections. Certainly, use-trauma as an etiologic concept in equine OA is widely accepted, and it seems likely that concussive forces act greatest distally. Likewise, perhaps the increased prevalence of OA in the metacarpophalangeal joint compared with the metatarsophalangeal joint is a reflection of unequal weight distribution between the fore- and hind feet.

Subluxation may be temporary and intermittent and is, again, usually the result of trauma, although in horses subluxation of the proximal interphalangeal joint without an obvious cause can occur.²⁴ The number of subluxations observed in this study is relatively high, especially because there is no mention of it as a clinical entity in literature on rhinoceroses. It could be that perhaps handling and storage of these specimens postmortem could have subtly manipulated the joints out of complete congruency, or it could be that rhinoceroses normally experience a small degree of subluxation with little to no observable ill effects.

The surface lucencies around the metaphyseal regions were an unexpected finding, because they are not a feature in other species such as horses or elephants, and their significance is unclear. Their uniformity, however, in both appearance and distribution, throughout many specimens of diverse origin (wild and captive, older and modern, of various species) suggests that they are a normal anatomic feature of rhinoceroses and most likely to be vascular channels, synovial fossae, or a combination and similar to the synovial fossa in the navicular bone of horses.

The apparently inconsistent presence of the distal sesamoid bone both between and within rhinoceros species may reflect a natural and incidental variation, a characteristic of many sesamoids,^{5,29} but it also may be due to accidental loss of the small bone from museum specimens, sometimes over a century old. The reported absence of the bone, especially in some species, notably black rhinoceroses, of which the number involved in this study was admittedly small, is thus an anecdotal finding requiring further investigation for testing.

Ideally, we would have like to have more data regarding these rhinoceroses when alive, because the clinical significance of some of the bony changes is difficult to interpret in the absence of such information. For example, it is unknown whether some of the pathologic lesions exhibited in their feet would have caused overt clinical signs in these animals; an unfortunate limitation of this study. Because of this lack of data, it is difficult to

advise on how the pathologic changes should be treated, or if treatment is necessary at all, especially in certain cases (e.g., subluxation), where the positions of foot bones may not be representative of their orientations in vivo. It must be stressed that this is a retrospective study and that the clinical significance of the described bony changes remains unknown. Therefore, it is important that future cases of clinical signs in rhinoceroses are reported in the literature in conjunction with data on pathologic conditions, or lack thereof, from radiographic or other data in vivo or else postmortem scanning or dissection, to test how often these two factors are in conjunction.

Acknowledgments. Thanks to Matthew Lowe at the Cambridge University Museum of Zoology, Roberto Portella Miguez at the Natural History Museum of London, and Malgosia Nowak-Kemp at the Oxford Museum of Natural History for help and hospitality while gathering data for this study. Expert advice from Tim Bouts also is gratefully acknowledged. We also thank Regina Pfistermuller and two anonymous reviewers for helpful comments on a previous draft of this manuscript. This research was funded by grant BB/H002782/1 from the Biotechnology and Biological Sciences Research Council (United Kingdom) to JRH and RW.

LITERATURE CITED

- Andrews, A. H. 2004. Diseases and Husbandry of Cattle. Bovine Medicine, 2nd ed. Blackwell Science, Oxford, United Kingdom.
- Baishya, G., A. Kalita, and A. Chakraborty. 2001. Anatomy of the distal sesamoid of Indian one-horned rhinoceros. *Indian Vet. J.* 78: 824–825.
- Baxter, G. M., and O. R. Adams. 2011. Adams and Stashak's Lameness in Horses, 6th ed. Wiley-Blackwell, Chichester, United Kingdom.
- Coombs, W. 1978. Theoretical aspects of cursorial adaptations in dinosaurs. *Q. Rev. Biol.* 53: 393–418.
- Dyce, K. M., W. O. Sack, and C. J. G. Wensing. 2010. Textbook of Veterinary Anatomy, 4th ed. Saunders Elsevier, St. Louis, Missouri.
- Emslie, R. 2001. *Ceratotherium simum*. <http://www.iucnredlist.org/details/4185/0>. Accessed 1 December 2011.
- Emslie, R. 2001. *Diceros bicornis*. <http://www.iucnredlist.org/details/6557/0>. Accessed 1 December 2011.
- Flach, E., T. Walsh, J. Dodds, A. White, and O. Crowe. 2003. Treatment of osteomyelitis in a greater one-horned rhinoceros (*Rhinoceros unicornis*). *Verh. Erkr. Zootiere* 41: 1–7.
- Fowler, M. E. 2001. An overview of foot conditions in Asian and African elephants. In: Csuti, B., E. L. Sargent, and U. S. Bechert (eds.). *The Elephant's Foot: Prevention and Care of Foot Conditions in Captive Asian and African Elephants*, 1st ed. Iowa State University Press, Ames, Iowa.
- Fowler, M. E., and S. K. Mikota. 2006. *Biology, Medicine, and Surgery of Elephants*, 1st ed. Blackwell Publishing, Ames, Iowa.
- Fowler, M. E., and R. E. Miller. 2003. *Zoo and Wild Animal Medicine*, 5th ed. Saunders, St. Louis, Missouri.
- Göltenboth, R., and F. von Houwald (eds.). *Husbandry Guidelines for Rhinoceroses. EEP Yearbook 1994/95 and 12th EEP Conference, Poznan*. Pp. 364–377.
- Harrison, T., B. Stanley, J. Sikarskie, G. Bohart, N. Ames, J. Tomlian, M. Marquardt, A. Marcum, M. Kiupel, D. Sledge, and D. Agnew. 2011. Surgical amputation of a digit and vacuum-assisted-closure (V.A.C.) management in a case of osteomyelitis and wound care in an eastern black rhinoceros (*Diceros bicornis michaeli*). *J. Zoo Wildl. Med.* 42: 317–321.
- von Houwald, F. 2001. Foot problems in Indian rhinoceroses (*Rhinoceros unicornis*) in zoological gardens: macroscopic and microscopic anatomy, pathology, and evaluation of the causes. Ph.D. dissertation, Univ. of Zurich, Zurich, Switzerland.
- von Houwald, F., and E. Flach. 1998. Prevalence of chronic foot disease in captive greater one-horned rhinoceros (*Rhinoceros unicornis*). *EAZWV Sci. Meet.* 2: 323–327.
- von Houwald, F., and G. Guldenschuh. 2002. *Husbandry Manual for the Greater One-Horned or Indian Rhinoceros (Rhinoceros unicornis) Linné, 1758*. Basel Zoo, Basel, Switzerland.
- Jacobsen, J. 2002. A Review of Rhino Foot Problems. In: *Proc. 2nd Rhino Keepers' Workshop 2001*. Zoological Society of San Diego, San Diego, California. Pp. 56–59.
- Jones, D. 1979. The husbandry and veterinary care of captive rhinoceroses. *Int. Zoo Yearb.* 19: 239–250.
- Mikota, S. K., E. L. Sargent, and G. S. Ranglack. 1994. *Medical Management of the Elephant*. Indira Publishing House, West Bloomfield, Michigan.
- Miller, C., C. Basu, G. Fritsch, T. Hildebrandt, and J. Hutchinson. 2008. Ontogenetic scaling of foot musculoskeletal anatomy in elephants. *J. R. Soc. Interface* 5: 465–475.
- Osofsky, S., D. Paglia, R. Radcliffe, R. Miller, R. Emslie, T. Foote, R. Du Toit, and M. Atkinson. 2001. First, do no harm: a precautionary recommendation regarding the movement of black rhinos from overseas zoos back to Africa. *Pachyderm* 30: 17–23.
- Panagiotopoulou, O., T. Pataky, Z. Hill, and J. Hutchinson. 2012. Statistical parametric mapping of the regional distribution and ontogenetic scaling of foot pressures during walking in Asian elephants (*Elephas maximus*). *J. Exp. Biol.* 215: 1584–1593.

23. Rhino Resource Center. 2011. Indian rhino - *Rhinoceros unicornis*. <http://www.rhinoresourcecenter.com/species/indian-rhino/>. Accessed 1 December 2011.
24. Ross, M. W., and S. J. Dyson. 2011. Diagnosis and Management of Lameness in the Horse, 2nd ed. Elsevier Saunders, St. Louis, Missouri.
25. Silberman, M., and R. Fulton. 1979. Medical problems of captive and wild rhinoceroses: a review of the literature and personal experiences. *J. Zoo Anim. Med.* 10: 6–16.
26. van Strien, N., B. Manullang, I. W. Sectionov, M. Khan, E. Sumardja, S. Ellis, K. Han, P. J. Boeadi, and E. Bradley Martin. 2011. *Dicerorhinus sumatrensis*. <http://www.iucnredlist.org/details/6553/0>. Accessed 1 December 2011.
27. van Strien, N., R. Steinmetz, B. Manullang, H. K. Sectionov, W. Isnani, K. Rookmaaker, E. Sumardja, M. Khan, and S. Ellis. 2011. *Rhinoceros sondaicus*. <http://www.iucnredlist.org/details/19495/0>. Accessed 1 December 2011.
28. Talukdar, B., R. Emslie, S. Bist, A. Choudhury, S. Ellis, B. Bonal, M. Malakar, B. Talukdar, and M. Barua. 2011. *Rhinoceros unicornis*. <http://www.iucnredlist.org/details/19496/0>. Accessed 1 December 2011.
29. Vickaryous, M. K., and W. M. Olson. 2007. Fins into Limbs: Evolution, Development, and Transformation, 1st ed. University of Chicago Press, Chicago, Illinois.
30. Warren-Smith, C. M. R., S. Danika, N. Saunders, T. Bouts, J. R. Hutchinson, and R. Weller. 2010. Radiographic and computed tomographic (CT) changes observed in the feet of captive elephants. EVDI, Annual European Conference, Giessen, Germany.

Received for publication 12 January 2013