

## SURGICAL AMPUTATION OF A DIGIT AND VACUUM-ASSISTED-CLOSURE (V.A.C.) MANAGEMENT IN A CASE OF OSTEOMYELITIS AND WOUND CARE IN AN EASTERN BLACK RHINOCEROS (*DICEROS BICORNIS MICHAELI*)

Tara M. Harrison, D.V.M., M.P.V.M., Dipl. A.C.Z.M., Bryden J. Stanley, B.V.M.S., M.Vet.Sc., M.A.C.V.Sc., Dipl. A.C.V.S., James G. Sikarskie, D.V.M., M.S., Dipl. A.C.Z.M., George Bohart, D.V.M., N. Kent Ames, D.V.M., M.S., Janice Tomlian, Mark Marquardt, B.S., M.A., Annabel Marcum, B.S., Matti Kiupel, D.V.M., Ph.D., Dipl. A.C.V.P., Dodd Sledge, D.V.M., Ph.D., Dipl. A.C.V.P., and Dalen Agnew, D.V.M., Ph.D., Dipl. A.C.V.P.

**Abstract:** A 14-yr-old female eastern black rhinoceros (*Diceros bicornis michaeli*) presented with progressive suppurative osteomyelitis in her left hind lateral toe.  $\beta$ -Hemolytic *Streptococcus* sp. was isolated. The animal was treated with multiple systemic antibiotics, and topical wound cleansing. Repeated debridements and nail trimmings were performed for 5 mo prior to electing amputation. The toe was surgically amputated under general anesthesia between the first and second phalanges. Analgesia was diffused into the wound topically via a catheter and elastomeric pump. The open amputation site was covered with adherent drapes and a negative-pressure wound therapy device provided vacuum-assisted closure (V.A.C.) for 72 hr. Three months later this animal developed a deep dermal ulcer on the lateral aspect of the right hind limb, at the level of the stifle. Methicillin-resistant *Staphylococcus aureus* was isolated. The wound was managed by initial daily lavage, followed by 1 mo of V.A.C. therapy, with 72 hr between dressing changes. Clinically, this therapy expedited the formation of healthy granulation tissue and overall healing was accelerated. The animal tolerated the machine and bandage changes well via operant conditioning. The use of negative-pressure wound therapy appeared to shorten time to resolution of slow-healing wounds in black rhinoceros.

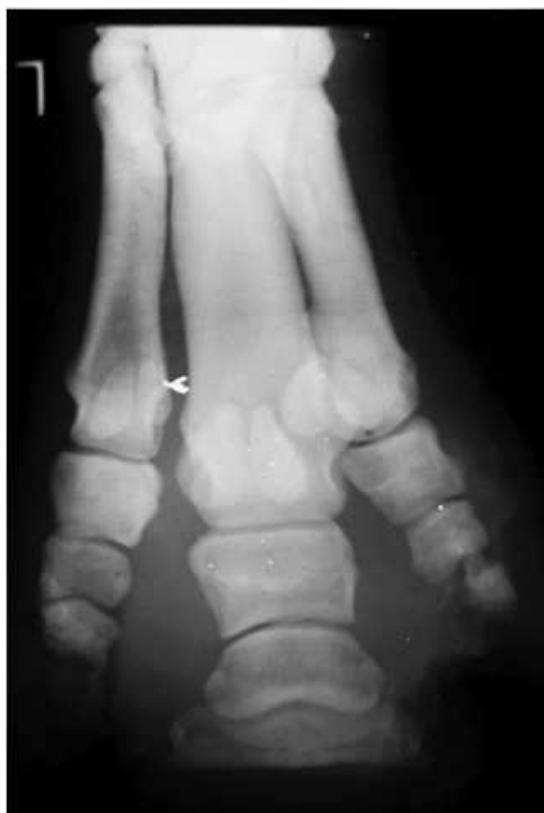**Key words:** Amputation, black rhinoceros, *Diceros bicornis michaeli*, MRSA, methicillin resistant *Staphylococcus aureus*, osteomyelitis, vacuum-assisted closure, V.A.C.

### BRIEF COMMUNICATION

A 14-yr-old, approximately 640-kg, female eastern black rhinoceros (*Diceros bicornis michaeli*) presented with a progressive swelling of the right hind lateral digit. The rhinoceros did not have any prior history of digit problems or other medical conditions. The animal was noticeably lame from the swollen digit. Antibiotic and anti-inflammatory therapy was initiated with phenylbutazone 3,000 mg p.o. q 48 hr for 14 doses (Vedco, St. Joseph, Missouri, 64507, USA) and trimethoprim sulfadiazine 20 g p.o. s.i.d. for 14 days (Uniprim, Macleod Pharmaceuticals, Inc., Fort Collins,

Colorado 80525, USA). Suppurative exudation was present near the nail. Culture yielded  $\beta$ -hemolytic *Streptococcus* sp. Antibiotics were continued based on antibiotic sensitivity findings. The swelling of the digit worsened, so a physical examination under general anesthesia was performed 3 mo after initial presentation. Anesthesia was induced and maintained with detomidine (10 mg i.m., Dormosedan, Pfizer Animal Health, New York, New York 10017, USA) and etorphine (3 mg i.m., Wildlife Pharmaceuticals, Fort Collins, Colorado 80522, USA). The nails were trimmed and the wound was flushed topically with dilute chlorhexidine and normal saline (2% chlorhexidine, 30 ml to 3.78 L normal saline [0.9% sodium chloride], Hospira, Inc., Lake Forest, Illinois 60045, USA). Lateral and anterior-posterior radiographs of both hind limbs were within normal limits at that time. The condition progressed to include the left hind lateral digit, which had become swollen and inflamed. A second physical examination was performed 6 mo after initial presentation using the same anesthetic protocol as previously described. The nails, foot pads, and necrotic portion of the nail were again trimmed and flushed. Radiographs of the digits of

From the Potter Park Zoo, 1301 South Pennsylvania, Lansing, Michigan 48912, USA (Harrison, Tomlian, Marquardt, Marcum); Michigan State University College of Veterinary Medicine, Veterinary Clinical Center, East Lansing, Michigan, 48824, USA (Harrison, Stanley, Sikarskie, Bohart, Ames); Diagnostic Center for Population and Animal Health, Michigan State University, 4125 Beaumont Road, East Lansing, Michigan 48910, USA (Kiupel, Sledge, Agnew). Correspondence should be directed to Dr. Harrison (taramharrison@gmail.com).

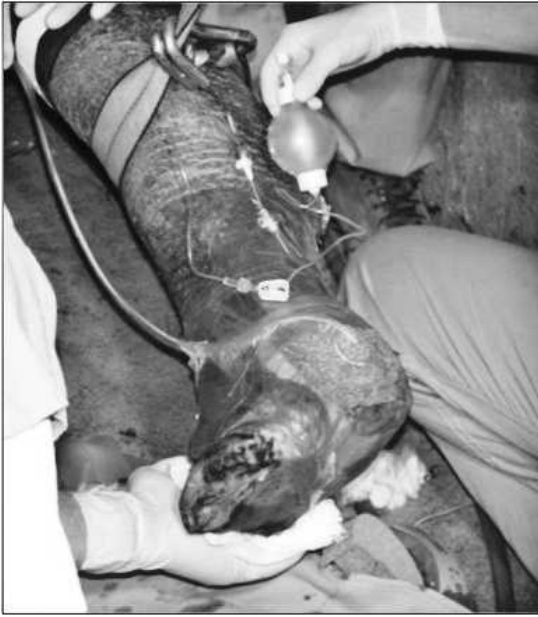

**Figure 1.** Radiograph of an eastern black rhinoceros with moderate to severe osteomyelitis of the left hind limb, third digit, second and third phalanges.

both hind limbs showed no evidence of osteomyelitis. However, the condition of the left hind lateral digit increased in severity with osteomyelitis seen by 7 mo, likely due to an increased stress load subsequent to lameness of the infected right foot. Additional antibiotics were administered (enrofloxacin 5.6 g p.o. s.i.d. for 60 days; Bayer Animal Health Care LLC, Shawnee Mission, Kansas 66201, USA) as well as continuing anti-inflammatory therapy (phenylbutazone 3,000 mg q 48 hr for 14 doses). The animal's lameness and infection of the digits continued to worsen. The nail of the left hind lateral digit sloughed associated with suppuration. Topical treatments such as flushing and scrubbing with chlorhexidine and betadine scrubs, as well as application of topical compounded dimethyl sulfoxide–furacin mixture and topical silver sulfadiazine cream (PAR Pharmaceutical, Inc., Spring Valley, New York 10977, USA), were initiated once a day. Medical treatments such as regional digital perfusion were

attempted but were not feasible due to limited operant conditioning of this animal.

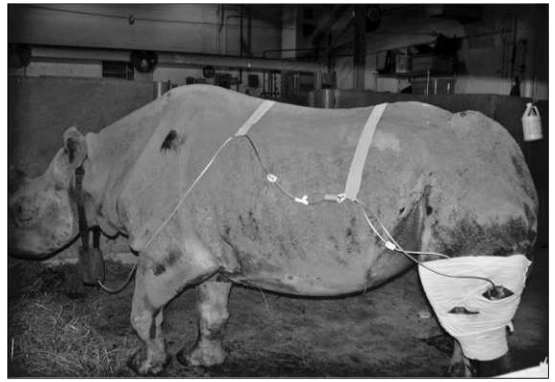Despite topical treatments and continued antibiotic therapy, the nails became overgrown and necrotic, and began to crack. A third immobilization was performed 8 mo after initial presentation using the same protocol as previously described. At this time, moderate to severe osteomyelitis was diagnosed based on radiographs of P2–P3 of the left hind digit 3 (Fig. 1). In addition, the animal tested positive for cold agglutinins associated with  $\beta$ -hemolytic *Streptococcus* sp. infection (Texas Veterinary Medical Diagnostic Laboratory, College Station, Texas, 77841 USA). At 10 mo after initial presentation the decision was made to amputate due to lack of improvement. Amputation of the lateral digit of the left hind limb was elected to remove the sequestrum of infected bone and to treat the resulting wound. The toe was surgically amputated at the level of the first and second phalanges under general anesthesia using the same protocol as previously used. Additional analgesia was provided with a Bier block, or intravenous regional analgesia performed by placing a tourniquet on the hind limb and injecting 30 ml of 2% lidocaine (IVX Animal Health Inc., St. Joseph, Missouri 64503, USA) i.v. via the saphenous vein distal to the tourniquet. Prolonged analgesia was provided through diffusion of 50 ml of 2% lidocaine and 50 ml of 0.75% bupivacaine (Hospira, Lake Forest, Illinois 60045, USA) topically into the wound via a catheter and elastomeric pump (Mila International, Erlanger, Kentucky 41018 USA). The surgical site was bandaged for 3 days and on the third day a vacuum-assisted closure device (V.A.C.<sup>®</sup>, Kinetic Concepts Incorporated, San Antonio, Texas 78265 USA) was applied. Application of the V.A.C. was achieved as follows. The bandage was removed, the site was cleaned with dilute nolvasan and saline as used previously, and a liquid adhesive (Mastisol,<sup>®</sup> Ferndale Laboratories, Ferndale, Michigan 48220, USA) was applied around the site. The V.A.C. was applied as per manufacturer directions by placing an open-cell polyurethane foam (Granufoam<sup>®</sup>, Kinetic Concepts Incorporated) over the wound and Ioban adhesive occlusive material (3M, St. Paul Minnesota 55144, USA) over the foam into which a perforated traction pad (T.R.A.C.<sup>®</sup> Pad, Kinetic Concepts Incorporated) was applied through a 2-cm fenestration in the Ioban<sup>®</sup> (Fig. 2). The tubing was then attached to the canister on the pump. The pump was hung in the manufacturer's carry-bag around the neck of the animal and the suction



**Figure 2.** Application of a vacuum-assisted closure device on an amputated digit of an eastern black rhinoceros with an elastomeric pump for analgesia.

tubing was run through loops of 0 polydioxanone (Ethicon, Inc., Somerville, New Jersey, 08876, USA) sutured to the skin along the side of the rhinoceros. Anesthesia was then reversed and the pump maintained at  $-120$  mm Hg intermittent suction. The V.A.C. therapy was monitored and remained in place for 72 hr, after which it was removed via operant conditioning. The wound appearance at this time revealed decreased exudation and the presence of early granulation tissue. Subsequently, the wound continued to heal by second intention.

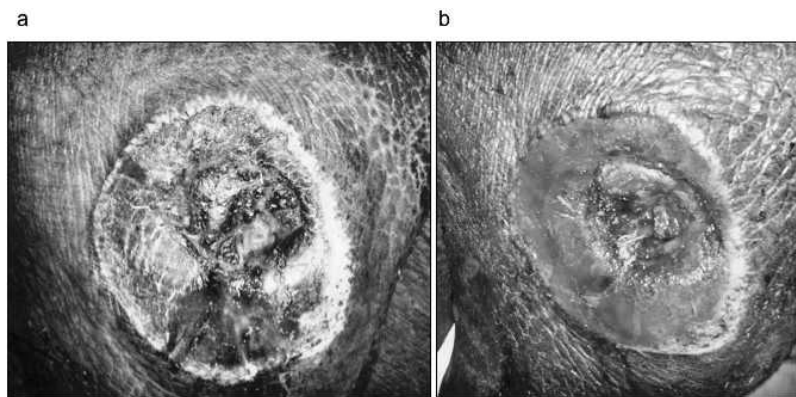
Thirteen months after the animal's initial presentation for lameness, the animal developed a 20-cm-diameter round ulceration on the lateral aspect of the right hind limb at the level of the stifle. Methicillin-resistant *Staphylococcus aureus* (MRSA) was cultured. A footbath protocol and mandatory use of latex gloves while treating this animal was instituted due to employee health concerns. Topical treatments including flushing with 0.05% chlorhexidine, scrubbing with 1% betadine solution, and application of silver sulfadiazine cream were not successful in reducing the size of the wound. After 22 days of topical management, it was elected to anesthetize this animal and apply the V.A.C. to the affected area to further treat the wound and decrease the employee health risks associated with wound treatment.



**Figure 3.** Eastern black rhinoceros with vacuum-assisted closure device applied to the left stifle. Devise was applied similar as described on the right side.

The rhinoceros was anesthetized with the protocol previously used, the site was surgically debrided and mechanically cleaned using a pulsatile lavage unit (Interpulse®, Stryker, Kalamazoo, Michigan 49002 USA), and the V.A.C. was applied as previously described (Fig. 3). The V.A.C. was left on for 72 hr, when the bandage was changed and the V.A.C. reapplied through operant conditioning of the animal. After 3 days, the wound had decreased in size and was granulating well (Fig. 4). However, the rhinoceros developed an ulceration on the left lateral hind limb at the level of the stifle. At this time, the animal, which had become increasingly anemic (packed-cell volume of 15%), collapsed, was unable to stand, and subsequently died 14 mo after initial presentation.

At necropsy, lesions consisted of severe osteomyelitis and laminitis of all four feet. The wound on the lateral stifle of the right limb was characterized by a severe focally extensive ulceration that extended into the mid- to deep dermis. The base of the ulcer was lined by variably thick rims of necrotic eosinophilic material, a thin band of granulation tissue infiltrated by a few neutrophils, and dense layers of maturing fibrosis. Vasculature in the layers of granulation tissue and fibrosis was lined by prominent plump endothelium and surrounded by a few lymphocytes, macrophages, and hemosiderin-laden macrophages. The epithelium along the margins of the ulcers was moderately hyperplastic and showed marked laminar ortho- and parakeratotic hyperkeratosis. In rare areas, the stratum corneum was infiltrated by moderate numbers of viable and degenerate neutrophils. Few bacteria and rare 4- to 10- $\mu$ m-diameter, thick-walled, roughly spherical fungal



**Figure 4.** Lateral lesion on the right hind limb at the level of the stifle in an eastern black rhinoceros. **a.** Before treatment. **b.** Three days after treatment with a vacuum-assisted closure device.

or yeast spores were dispersed throughout the necrotic debris overlying the ulcer. Other lesions noted at necropsy were chronic necrotizing aspiration pneumonia, ulcerative gastritis, a left shift of erythroid and myeloid series in the bone marrow, hydrothorax, hydroperitoneum, and hydropericardium.

The V.A.C. system has been used extensively in humans, as well as in dogs, a cat, turtles, a tortoise, an equine, and a juvenile tiger.<sup>1-5,7-10,14,16-19,21</sup> Prior to the use in this rhinoceros, the V.A.C. had not been used to manage wounds in megavertebrates. Megavertebrates can develop ulcerative lesions due to inadequate cement flooring as well abnormal weight-bearing, which could be anatomic or as a result of shifting weight due to lesions. Further, management and treatment of limb wounds has been challenging in megavertebrates and is often associated with conformational abnormalities.<sup>12</sup> Negative-pressure therapy promotes growth of granulation tissue and more rapid healing of large wounds that are otherwise difficult to manage.<sup>6,11,13,20</sup> The size of this patient made frequent anesthesia, debridements, and bandage changes logistically difficult. The V.A.C. allowed for less-frequent bandage changes, assisted in responsible management of a potential employee health hazard (MRSA), and potentially allowed more rapid wound healing.

Complications to healing in this case were attributed to other conditions this animal developed during the 14 mo of treatment, including MRSA and anemia due to either chronic infection or hemolytic anemia syndrome described in other black rhinoceros.<sup>15</sup> In addition to the anemia, this animal had tested positive for cold agglutinins associated with  $\beta$ -hemolytic *Streptococcus*, as well as other infections. Agglutinins can result in

anemia, which may have resulted in decreased blood flow to the limbs thereby causing laminitis and wounds that required frequent medical treatment. The additional complications that this animal developed, including pneumonia, were expected based on the long duration of treatment and slow anesthetic recovery during the last procedure. The left shift in the erythroid and myeloid series was not noted peripherally other than as a severe anemia. The hydrothorax, hydroperitoneum, and hydropericardium, however, were not diagnosed until necropsy.

The V.A.C. and bandages were easily applied during operant conditioning sessions, except on the foot. Ideally, the V.A.C. should have been reapplied to the foot, but it was not possible without general anesthesia to apply the bandage and encompass the underside of the foot; therefore, a one-time V.A.C. treatment was used on the foot amputation site. However, the brief application of the V.A.C. appears to have facilitated more rapid wound healing of the foot lesion than if only bandages had been applied.

In conclusion, the V.A.C. may be ideal for many zoological medicine applications, and under the right conditions, may greatly improve wound care, particularly in megavertebrates with skin ulcerations or wounds.

**Acknowledgments:** The authors would like to thank Kinetic Concepts, Incorporated, for the donation of machines and dressings, as well as technical support, with an extra thank you to Vickie Wardlaw, R.N., and Linda Shocklee, R.N., for their advice and assistance. The authors would also like to thank all the Potter Park Zoo staff for their assistance in this case as treatment would have not been possible without operant condi-



tioning training of this animal. Additionally, we would like to thank Dr. Michele Miller for her consultation and assistance. Thanks also to Dr. Albert Lewandowski, Dr. Christopher Bonar, Ron Blum, the Lansing Fire Department Station 5, Dr. Paul Coe, Dr. Chris Tabaka, and the Michigan State University College of Veterinary Medicine veterinarians, technicians, and students for their extensive help in this case.

### LITERATURE CITED

1. Adkeson, M., E. K. Travis, M. A. Weber, J. P. Kirby, and R. E. Junge. 2007. Vacuum-assisted closure for treatment of a deep shell abscess and osteomyelitis in a tortoise. *J. Am. Vet. Med. Assoc.* 8: 1240–1254.
2. Ahmed, M., T. Soskova, and D. T. Williams. 2007. Regarding “state-of-the-art treatment of chronic leg ulcers: a randomized controlled trial comparing vacuum-assisted closure (V.A.C.) with modern wound dressings.” *J. Vasc. Surg.* 46: 614–615; authors’ reply 615–616.
3. Ben-Amotz, R. O., O. I. Lnaz, J. M. Miller, D. E. Filipowicz, and M. D. King. 2007. The use of vacuum-assisted closure therapy for the treatment of distal extremity wounds in 15 dogs. *Vet. Surg.* 36: 684–690.
4. Coke, R. L., P. A. Reyes-Fore, and A. D. Finkelstein. 2006. Treatment of a carapace abscess in an Aldabra tortoise. *J. Herp. Med. Surg.* 16: 102–106.
5. Eneroth, M., and W. H. van Houtum. 2008. The value of debridement and vacuum-assisted closure (V.A.C.) therapy in diabetic foot ulcers. *Diabetes-Metab. Res. Rev.* 24 (Suppl 1): S76–80.
6. Fisher, A., and B. Brady. 2003. Vacuum assisted wound closure therapy. *Issues Emerg. Health Technol.* 44: 1–6.
7. Gemeinhardt, K. D., and J. A. Molnar. 2010. Vacuum-assisted closure for management of a traumatic neck wound in a horse. *Eq. Vet. Ed.* 17: 27–33.
8. Lafortune, M., G. J. Fleming, J. L. Wheeler, T. Gobel, and D. W. Moningo. 2007. Wound management in a juvenile tiger (*Panthera tigris*) with vacuum-assisted closure (V.A.C. therapy). *J. Zoo Wildl. Med.* 2: 341–344.
9. Lafortune, M., J. F. X. Wellehan, D. J. Heard, E. Rooney-DelPino, C. V. Fiorello, and E. R. Javcobson. 2005. Vacuum-assisted closure (turtle VAC) in the management of traumatic shell defects in chelonians. *J. Herp. Med. Surg.* 4: 4–8.
10. Leffler, M., R. E. Horch, A. Dragu, and A. D. Bach. 2010. The use of the artificial dermis (Integra) in combination with vacuum assisted closure for reconstruction of an extensive burn scar—a case report. *J. Plast. Reconstr. Aesthet. Surg.* 63: 32–35.
11. Leininger, B. E., T. E. Rasmussen, D. L. Smith, D. L. Jenkins, and C. Copolla. 2006. Experience with wound VAC and delayed primary closure of contaminated soft tissue injuries in Iraq. *J. Trauma* 5: 1207–1211.
12. Luikart, K. A., and S. M. Stover. 2005. Chronic sole ulcerations associated with degenerative bone disease in two Asian elephants (*Elephas maximus*). *J. Zoo Wildl. Med.* 36: 684–688.
13. Mendez-Eastman, S. 1998. Negative pressure wound therapy. *Plast. Surg. Nurs.* 18: 27–29, 33–27.
14. Morykwas, M. J., L. C. Argenta, E. I. Shelton-Brown, and W. McGuirt. 1997. Vacuum-assisted closure: a new method for wound control and treatment: animal studies and basic foundation. *Ann. Plast. Surg.* 38: 553–562.
15. Murray, S., N. P. Lung, T. P. Alvarado, K. C. Gamble, M. A. Miller, D. E. Paglia, and R. J. Montali. 2000. Idiopathic hemorrhagic vasculopathy syndrome in seven black rhinoceros. *J. Am. Vet. Med. Assoc.* 15: 230–233.
16. Owen, L., A. Hotston-Moore, and P. Holt. 2009. Vacuum-assisted wound closure following urine-induced skin and thigh muscle necrosis in a cat. *Vet. Comp. Orthop. Traumatol.* 22: 417–421.
17. Pollak, A. N. 2008. Use of negative pressure wound therapy with reticulated open cell foam for lower extremity trauma. *J. Orthop. Trauma* 22: S142–145.
18. Sibbald, R. G., and K. Y. Woo. 2008. V.A.C. therapy in home care. *Int. Wound J.* 5(Suppl. 2): iii–iv.
19. Turek, D., I. Netuka, J. Maly, O. Szarszoi, J. Besik, M. Urban, J. Pirk, and V. Petkov. 2009. Management of deep device related infection in patient implanted with mechanical cardiac support device using V.A.C. system. *Rozhl Chir.* 88: 693–696.
20. Venturi, M. L., C. E. Attinger, A. N. Mesbahi, C. L. Hess, and K. S. Graw. 2005. Mechanisms and clinical applications of the vacuum-assisted closure (VAC) device: a review. *Am. J. Clin. Dermatol.* 6: 185–194.
21. Vuerstaek, J. D., T. Vainas, J. Wuite, P. Nelemans, M. H. Neumann, and J. C. Veraart. 2006. State-of-the-art treatment of chronic leg ulcers: a randomized controlled trial comparing vacuum-assisted closure (V.A.C.) with modern wound dressings. *J. Vasc. Surg.* 44: 1029–1037; discussion 1038.

Received for publication 1 September 2010