

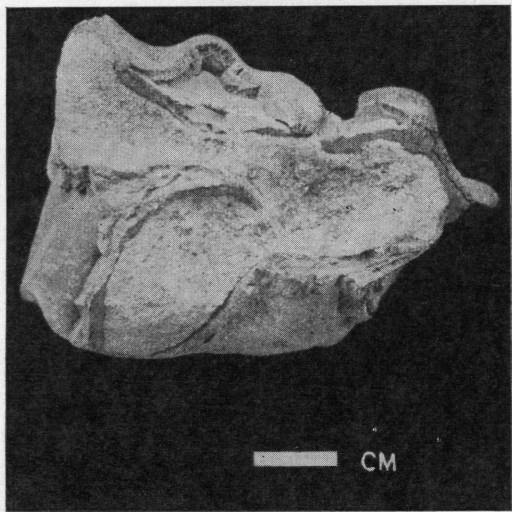fig. 1 : Crown view of a milk molar

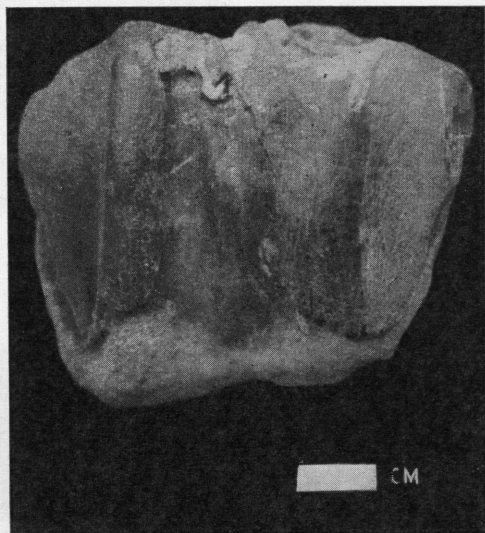


fig. 2 : Buccal view of a milk molar

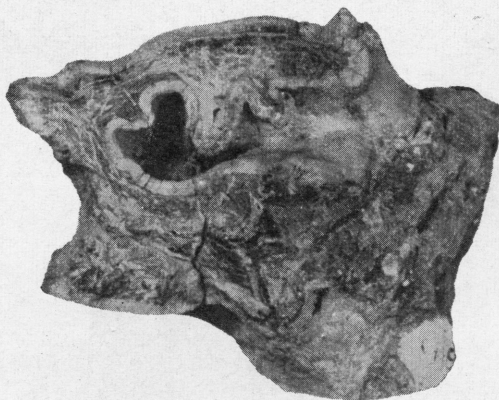


fig. 3 : S/5, Crown view of LM³

Rhinoceros palaeindicus Falconer and Cautley
(All figures approximately three — fourth natural size).




fig. 1 : Ind. Mus. No. C 65, Crown view of mandibular symphysis

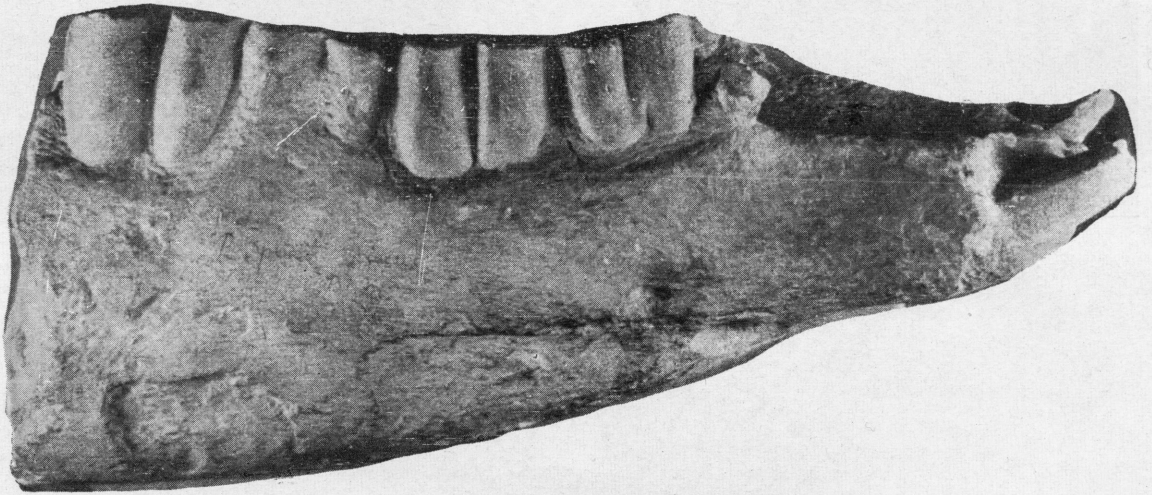


fig. 2 : Lateral view of the above

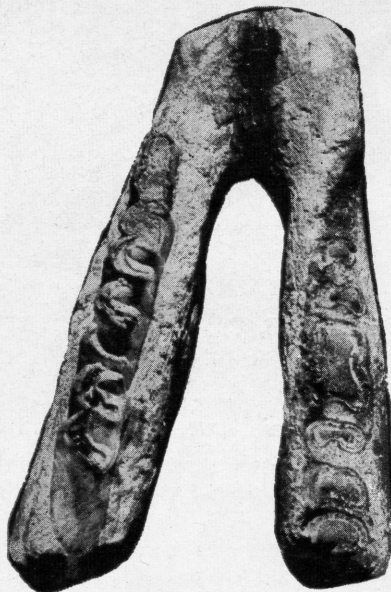

fig. 3 : S/6, Crown view of mandibular symphysis
Rhinoceros palaeindicus Falconer and Cautley

(figs. 1 & 2 approximately one-half natural size; fig. 3 approximately one-fourth natural size).